

A Study on Variations of Branching Pattern of Renal Artery with its Clinical Significance

Mansur DI,¹ Karki S,² Mehta DK,¹ Shrestha A,¹ Dhungana A¹

¹Department of Anatomy

²Department of Radio-diagnosis

Kathmandu University School of Medical Sciences

Dhulikhel, Kavre, Nepal.

Corresponding Author

Dil Islam Mansur

Department of Anatomy

Kathmandu University School of Medical Sciences,

Dhulikhel, Kavre, Nepal.

E-mail: dilislam@kusms.edu.np

Citation

Mansur DI, Karki S, Mehta DK, Shrestha A, Dhungana A. A Study on Variations of Branching Pattern of Renal Artery with Its Clinical Significance. *Kathmandu Univ Med J.* 2019;66(2):136-40.

ABSTRACT

Background

The kidneys are supplied by a single renal artery originating from abdominal aorta. However, recent literature reports great variations in renal blood supply. Hence, it becomes mandatory for the clinicians to understand the abnormality and variations in the renal vasculature.

Objective

To evaluate the branching pattern of renal artery and its variations.

Method

The study consisted of Computed Topographic images of 206 kidneys. Numbers and branching pattern of renal artery were recorded. The data was analyzed for presence or absence, source of origin and type of accessory renal artery.

Result

The present study revealed that 73.79% of kidneys were supplied by a single renal artery, 25.72% by double renal artery and 0.49% by triple renal artery. The hilar branching pattern was recorded in 38.83% and early branching pattern was in 34.95%. The presence of accessory renal artery was recorded in 26.21%. They were originated from abdominal aorta in 22.81% and 3.40% from main renal artery. The prevalence of superior polar artery was found in 6.79%, hilar in 10.19% and inferior polar in 9.22%.

Conclusion

The knowledge of variations of renal artery becomes essential for the clinician to plan the adequate surgical procedures and to avoid any vascular complication.

KEY WORDS

Abdominal aorta, Accessory renal artery, Renal artery

INTRODUCTION

The kidneys usually have rich blood supply, nearly 20% of cardiac output for filtration through the renal arteries (RA) which are a pair of lateral branches from abdominal aorta.¹ Normally each kidney receives one RA which is present in approximately 70% of individuals.² However, accessory RA can also exist. The RA usually enters into the renal parenchyma via its hilum whereas the accessory RA might enter through the hilum or the surfaces of the kidney.³ These accessory RA account for about 30% of individuals.⁴ They are regarded as persistent embryonic lateral splanchnic arteries.²

Variations in the number and branching pattern of the RA are extremely common and showed social, ethnic and racial differences.^{1,5} The occurrence of accessory RA can be a problem for the clinicians because they do not anastomose intrarenally and each one nourishes only a segment of the renal parenchyma.⁶

The hydronephrosis may be produced by obstructing ureter when inferior polar arteries cross anterior to the ureter.² The kidney is the most common organ for transplantation in the present day, which involves vascular reconstruction.⁷ The knowledge and awareness of these possible variations of the RA are essential for sufficient surgical management during urological procedures and abdominal imaging studies.⁸

Many studies have revealed racial differences in RA among various ethnic groups throughout the world.⁵ However, very few studies have been conducted in Nepalese population.⁹ Hence, this study is aimed to determine the number and branching pattern of RA; and to study the variations in accessory RA using Computed Tomographic (CT) images which would be helpful for the clinicians during their clinical practices.

METHODS

This is the cross sectional, retrospective and observational study. It was conducted on the CT images of 206 kidneys (103 right and 103 left) of 103 patients (49 male and 54 female) who had gone for CT angiography of abdomen for the diagnostic purpose in the Department of Radio-Diagnosis, Dhulikhel Hospital, Kathmandu University Hospital, Dhulikhel, Nepal during the period of November 2017-October 2018. The images of CT scans with an arterial phase covering the abdominal aorta and iliac arteries were included for the study. The images with incomplete demographic data, without adequate arterial phases or individuals who had prior nephrectomy were excluded from the study. Prior to the study, approval for the study was taken from IRC-KUSMS. The collected renal angiographic images were analyzed for branching pattern of RA and its variations.

The artery supplying the kidney is called renal artery. It may be single, double or triple. The artery which gives branches within or near renal hilum was considered as hilar branching pattern and branches away from renal hilum was considered as early branching pattern. The kidney which is supplied by more than single RA was considered as accessory renal artery (ARA). ARA may either arise from abdominal aorta or renal artery. ARA may be of different types as superior polar artery (SPA), hilar artery (HA) and inferior polar artery (IPA). Artery entering the superior pole, hilum and inferior pole was SPA, HA and IPA respectively.⁸ The artery entering other than the hilum was considered as aberrant artery.¹⁰

RESULTS

The present study revealed 152 (73.79%) kidneys had normal RA whereas 54 (26.21%) had variations in RA.

Number of Renal Artery (RA)

It was observed that 152 (73.79%) kidneys were supplied by a single RA and 54 (26.21%) were supplied by more than one RA. Out of which, 53 (25.72%) of kidneys had double RA and 1 (0.49%) had triple RA. In the right side, 26 (12.62%) kidneys were supplied by double RA and 1 (0.49%) by triple RA (Fig 2). Whereas 27 (13.10%) kidney were supplied by double RA and none of the cases was observed for three or more RA in the left side as shown in fig. 1 and 2; and Table 1.

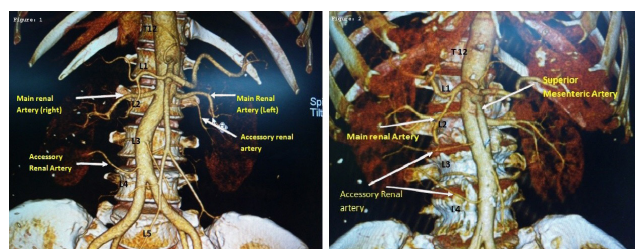


Figure 1. CT angiogram showing the presence of double renal artery on both sides **Figure 2.** CT angiogram showing the presence of triple renal artery in right side

Table 1. Number of renal artery

Number of renal artery	Right side		Left side		Total	
	Frequency	(%)	Frequency	(%)	Frequency	(%)
1	76	36.89	76	36.89	152	73.79
2	26	12.62	27	13.11	53	25.72
3	1	0.49	-	-	1	0.49
Total	103	50.00	103	50.00	206	100

Branching pattern of Renal Artery

The hilar branch pattern was recorded in 80 (38.83%) kidneys and early branching pattern was recorded in 72 (34.95%). On the right side, the hilar branch was in 51 (24.75%) and early branching was in 39 (18.93%) whereas 29 (14.08%) of hilar and 33 (16.02%) of early branching was recorded on the left side as illustrated in fig. 3 and table 2.

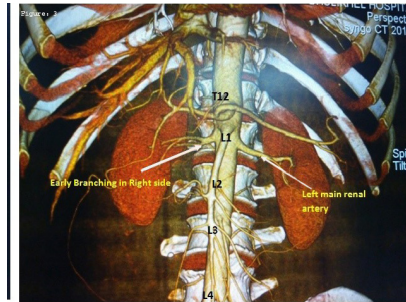


Figure 3. CT angiographic image showing the presence of early branching in the right renal artery

Table 2. Branching pattern of renal artery

Side	Hilar branch		Early branch		Total	
	Frequency	%	Frequency	%	Frequency	%
Right	51	24.75	39	18.93	90	43.69
Left	29	14.08	33	16.02	62	30.10
Total	80	38.83	72	34.95	152	73.79

Presence of Accessory Renal Artery (ARA)

The presence of ARA was found in 54 (26.21%) kidneys. Out of these, right ARA was found in 28 (13.59%) and left ARA was found in 26 (12.62%) as shown in fig. 1 and 2. The presence of ARA was found to be higher in male (N=33, 16.01%) as compared to female (N=21, 10.19%) as shown in table 3.

Table 3. Accessory renal artery

Side	Male		Female		Total	
	Frequency	%	Frequency	%	Frequency	%
Right	18	8.73	10	4.85	28	13.59
Left	15	7.28	11	5.34	26	12.62
Total	33	16.01	21	10.19	54	26.21

Source of origin of ARA

ARA originating from abdominal aorta was found to be in 47 (22.81%) kidneys. Out of which, 24 (11.65%) ARA was found on the right side and 23 (11.16%) on the left side. Similarly ARA arising from main RA was found in 7 (3.40%) kidneys. Out of which 4 (1.94%) was found on the right side and 3 (1.46%) on the left side as shown in fig. 4 and table 4.

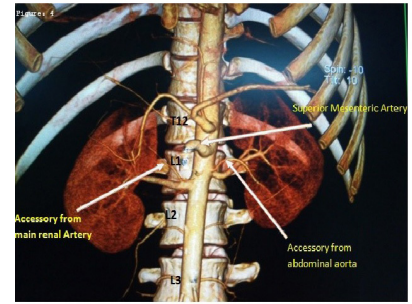


Figure 4. CT angiographic image showing the origin of Accessory Renal Artery,

Table 4. Source of origin of accessory renal artery

Side	Abdominal aorta		Main renal Artery		Total	
	Frequency	%	Frequency	%	Frequency	%
Right	24	11.65	4	1.94	28	13.59
Left	23	11.16	3	1.46	26	12.62
Total	47	22.81	7	3.40	54	26.21

Type of ARA

SPA were present in 14 (6.79%) ARA. Out of which, right SPA were present in 6 (2.91%) and left in 8 (3.88%) as shown in fig. 5. Likewise, HA were present in 21 (10.19%) of ARA. Out of that, right HA were present in 14 (6.79%) and left in 7 (3.39%). Similarly IPA were present in 19 (9.22%) of ARA. Out of that, right IPA were present in 8 (3.88%) and left in 11 (5.34%) as shown in fig. 6 and table 5.

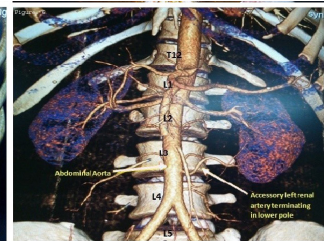
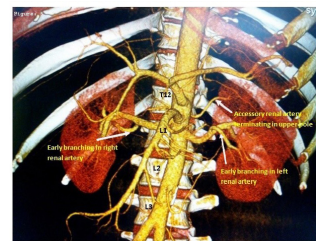


Figure 5. CT angiographic image showing left accessory renal artery to upper pole of kidney (SPA)

Figure 6. Showing termination of left accessory renal artery in lower pole (IPA)

Table 5. Type of accessory renal artery

Side	Right		Left		Total		
	Frequency	%	Frequency	%	Frequency	%	
Aberrant artery	SPA	6	2.91	8	3.88	14	6.79
	IPA	8	3.88	11	5.34	19	9.22
Total aberrant artery		14	6.79	19	9.22	33	16.02
HA		14	6.80	7	3.39	21	10.19
Total		28	13.59	26	12.61	54	26.21

Aberrant artery

The present study also concluded that aberrant artery was found in 33 (16.02%). Among them, 14 (6.79%) were found on the right side whereas 19 (9.22%) on the left side as shown in table 5.

DISCUSSION

The branching patterns of RA and its variations have been extensively studied in the present study and knowledge of variations plays vital role for surgeons in performing surgery and may help to minimize the clinical complications. In the present study, incidence of normal RA was found similar with South Indian population.¹¹ But higher incidences were recorded amongst Greece, Columbian and Turkish population.¹²⁻¹⁴ However Korean population showed lower incidence.¹⁵

Double RA was also recorded in the present study which is supported by Satyapal et al. and Saldarriaga et al.^{8,13} In contrast, Khamanarong et al; and Odman and Ranniger found the lesser incidence of double RA.^{16,17} Similarly, there was presence of triple RA in the present study which is comparable with a study conducted in Thailand.¹⁶ The transplantation of kidney with the single artery is technically easier compared to the kidney with multiple arteries.¹¹

The previous study has reported hilar branching pattern which is in contrast to the present study.¹¹ Tarzamni et al. reported early branching pattern which is comparable with this study.¹⁸ In contrast to these, Rao et al. reported early branching pattern in 88.46%.¹⁹ Sasikala et al. observed early branching pattern in 26%.²⁰ Thakur et al. noted early branching pattern in 17.5% of individuals.⁹

One of the previous studies has reported an incidence of early branching pattern in 9.4% on the right side and 16.5% on the left side which is different from the present study.¹³ The early branching pattern could have been due to delay in communication between the factors present in mesenchyme of the blood vessel and metanephros.¹⁸

Studies in Libian and Turkish population also documented ARA which is similar to the present study.^{21,22} A report has showed the incidence of ARA in Thai population which is dissimilar to the present study.¹⁶ Moreover there are a few data in the previous studies which are quite higher than the present study.^{23,24} Frequency of ARA may differ due to sample size, type of study and geographical variations.

There was discrepancy in the literature regarding ARA; some authors reported a higher frequency on the right side.^{14,16} Others on the left side but some noticed no significant differences.^{1,8,25,26} Moreover the present study showed 13.59% and 12.62% ARA on the right and left side respectively. The occurrence of ARA was higher in male than female in the present study which is comparable to a study done by Sasikala et al.²⁰

Similar to this study, authors quoted 20% of ARA originated from abdominal aorta and 8.33% from RA.¹¹ Whereas the higher incidence of ARA from abdominal aorta was recorded by Budhiraja et al. and Talovic et al.^{27,28} It is clear that the dominancy of aortic origin is more than that of renal origin.

SPA was also reported by many authors which is agreeable to the present study.^{16,26} The authors declared the higher incidence of SPA.^{27,29} However the lesser incidence of SPA was also recorded.^{28,30} HA was recorded in this study which is comparable with other studies.^{11,13} Ankolekar and Sengupta reported 13.33% of right HA and 10% of left HA which is higher than the present study.¹¹

Talovic et al. noted IPA which is in accordance with the present study.²⁸ The authors also declared the higher frequency of IPA.^{29,31} However, its lesser frequency was also recorded.^{16,24} From above findings it is clear that the majority of ARA enter through the inferior pole than the superior pole of the kidney. This is due to the fact that kidneys ascend from the pelvic region during embryonic life; the most likely ARA which fail to degenerate and will remain in the inferior pole of the kidney.^{11,32} In contradiction with the above results, there are studies which claimed that there was the majority of SPA than IPA.^{16,24} The present study revealed an aberrant artery which is also noticed by Hellstrom and Edsman.^{33,34}

This study is based only on CT scan images of the patients of Dhulikhel Hospital. So, it could not cover large sample size. It may not be generalized to all Nepalese populations.

CONCLUSION

It is clearly indicated that the RA has frequent variations. Most of the variations are seen in the number and branches of RA; and presence of ARA. The ARA also shows wide variations in origin and type of branching pattern. Hence, the knowledge of variations of RA has wide clinical, surgical and academic implications. It is also important for surgeons in performing many procedures and may help to avoid clinical complications in the abdominal region.

REFERENCES

1. Bordei P, Sapte E, Iliescu D, Dina C. The morphology and the surgical importance of the gonadal arteries originating from renal artery. *Surg Radiol Anat.* 2007; 29(5):367-71.
2. Standring S. *Gray's Anatomy. The anatomical basis of clinical practice.* 40th ed., Edinburgh, Churchill and Livingstone 2008; 1231-33.
3. Mir NS, Hassan AU, Rangrez R, Hamid S, Tabish SA, Rasool Z, et al. Bilateral duplication of renal vessels: Anatomical, medical and surgical perspective. *Int J Health Sci.* 2008;2:179-85.
4. Goswami P, Yadav Y, Chakradhar V. Morphological study of renal vasculature in North India. *European Journal of Academic Essays.* 2014; 1(2): 76-79.
5. Kadir S. *Atlas of normal and variant angiographic anatomy.* Philadelphia: WB Saunders Company. 1991; 387-429.
6. Rubin GD, Alfrey EJ, Dake MD, Semba CP, Sommer FG, Kuo PC, et al. Assessment of living renal donors with spiral CT. *Radiology.* 1995; 195:457-62.
7. Munnusamy K, Kasirajan SP, Gurusamy K, Raghunath G, Bolshetty SL, Chakrabarti S, et al. Variations in branching pattern of renal artery in kidney donors using CT angiography. *J Clin Diagn Res.* 2016; 10:18-21.
8. Satyapal KS, Haffejee AA, Singh B, Ramsaroop L, Robbs JV, Kalideen JM. Additional renal artery: Incidence and morphometry. *Surg Radiol Anat.* 2000; 23: 33-8.
9. Thakur D, Sedhain S, Luitel B, Chalise P, Sharma U, Gyawali P. Anatomical variations of renal artery in Nepalese live kidney donors. *J Inst Med.* 2016; 39:11-5.
10. Graves FT. The aberrant renal artery. *J Anat.* 1956; 90:553-58.
11. Ankolekar V, Sengupta R. Renal artery Variations: A cadaveric study with clinical relevance. *Int J Cur Res Rev.* 2013; 05(05):154-61.
12. Natsis K, Paraskevas G, Panagouli E, Tsaraklis A, Lolis E, Piagkou M et al. A morphometric study of multiple renal arteries in Greek population and a systematic review. *Rom J Morphol Embryol.* 2014; 55:1111-22.
13. Saldarriaga B, Perez A, Ballesteros L. A direct anatomical study of additional renal artery in a Colombian mestizo population. *Folia Morphol.* 2008; 67(2):129-34.
14. Ozkan U, Oguzkurt L, Tercan F, Kizilkilic O, Koc Z, Koca N. Renal artery origins and variations: angiographic evaluation of 855 consecutive patients. *Diagn Interv Radio.* 2006;12:183-6.
15. Chai JW, Lee W, Yin YH, Jae HJ, Chung JW, Kim HH, et al. CT angiography for living kidney donors: accuracy, cause of misinterpretation and prevalence of variation. *Korean J Radiol.* 2008;9:333-9.
16. Khamanarong K, Prachaney P, Utararavivhien A, Tong Un T, Sriporaya K. Anatomy of renal arterial supply. *Clinical anatomy.* 2004;17(4): 334-6.
17. Odman P, Ranniger K. The location of the renal artery: An angiographic and post mortem study. *Am J Roentgenol.* 1968;104:283-8.
18. Tarzamni MK, Nezami N, Rashid RJ, Argani H, Hajealioghli P, Ghorashi S. Anatomical differences in the right and left renal arterial patterns. *Folia Morphol.* 2008; 67(2):104-10.
19. Rao NS, Kishore K, Sujatha K, Rao HRK. Extra hilar branching of renal artery: An anatomical study. *Int J Anat Res.* 2015; 3(4):1568-72.
20. Sasikala P, Sulochana S, Rajan T, Mohan J, Rajendran SM. Comparative study of anatomy of renal artery in correlation with the computed tomography angiogram. *World J Med Sci.* 2013; 8:300-5.
21. Mishra A, Ehtuish EF. The pattern of renal vessels in live related potential donors pool. A multislice computed tomography angiography review. *Saudi Med J.* 2006; 27:841-4.
22. Gumus H, Bukte Y, Ozdemir E, Cetinçakmak MG, Tekbaş G, Ekici F, et al. Variations of RA in 820 patients using 64-detector CT-angiography. *Ren Fail.* 2012; 34:286-90.
23. Glodny B, Cromme S, Reimer P, Lennarz M, Winde G, Vetter H. Hypertension associated with multiple renal artery may be renin dependent. *J of Hypertens.* 2000; 18(10):1437-44.
24. Palmieri BJ, Petroianu A, MG TCBC, silva LC, Andrade LM, Alberti LR. Study of arterial pattern of 200 renal pedicle through angiotomography. *Rev Col Bras Cir.* 2011; 38(2): 116-21.
25. Merklin RJ, Michels NA. The variant renal and suprarenal blood supply with data on the inferior phrenic, ureteral and gonadal arteries: A statistical analysis based on 185 dissections and review of the literature. *J Int Coll Surg.* 1958; 29:41-76.
26. Sampaio FJ and Passos MA. Renal artery: Anatomic study for surgical and radiological practice. *Surg Radiol Anat.* 1992; 4:113-7.
27. Budhiraja V, Rastogi R, Asthana A. Renal artery variations: Embryological basis and surgical correlation. *Rom J Morphol Embryol.* 2016; 51:533-6.
28. Talovic E, Kulenovic A, Voljevic A, Kapur E. Review of the supernumerary renal artery by dissection method. *Acta Medica Academica.* 2007; 36:59-69.
29. Vatsala AR, Ajay KT, Mavishettar GF, Sangam. A study on branching pattern of renal artery. *Int J Anat Res.* 2014;2(1):270-2.
30. Cicekcibasi AE, Ziylan T, Salbacak A, Seker M, Buyukmumcu M, Tuncer I. An investigation of the origin, localization and variations of the renal artery in human fetuses and their clinical relevance. *Ann Anat.* 2005; 187:421-7.
31. Weld KJ, Bhayani SB, Belani J, Ames CD, Hruby G, Landman J. Extrarenal vascular anatomy of kidney: Assessment of variations and their relevance to partial nephrectomy. *Urology.* 2005; 66(5):985-9.
32. He B, Hamdorf JM. Clinical importance of anatomical variations of renal vasculature during laparoscopic donor nephrectomy. *OA Anatomy.* 2013; 1(3):25.
33. Hellstrom J. A contribution to the knowledge of the relation of abnormally running renal vessels to hydronephrosis, and an investigation of the arterial conditions in fifty kidneys. *Acta chir scand.* 1927; 61:289-330.
34. Edsman G. Accessory vessels of the kidney and their diagnosis in hydronephrosis. *Acta Radiol.* 1954;42:26-32.