

Permcath - A Vascular Access for Hemodialysis, Our Experience in Last Two Years

Baidya PR,¹ Shrestha K,² Deuja ML,³ Rai A,³ Shrestha N,³ Shrestha A,⁴ Baidya A⁵

¹Department of Cardiothoracic and Vascular Surgery,

²Department of Nephrology,

³Department of Anesthesia,

Sahid Dharma Bhakta National Transplant Center,
Bhaktapur, Nepal.

⁴Department of Anesthesia, Nidan Hospital,
Pulchowk, Nepal.

⁵Intern, Nepal Medical College

Jorpati, Kathmandu.

Corresponding Author

Prem Raj Baidya

Department of Cardiothoracic and Vascular Surgery,

Sahid Dharma Bhakta National Transplant Center,

Bhaktapur, Nepal.

E-mail: prembaidya@hotmail.com

Citation

Baidya PR, Shrestha K, Deuja ML, Rai A, Shrestha N, Shrestha A, et al. Permcath - A Vascular Access for Hemodialysis, Our Experience in Last Two Years. *Kathmandu Univ Med J.* 2019;68(4):263-6.

ABSTRACT

Background

The double lumen tunneled catheter (Permcath) is mostly used as an alternative access, not as a temporary access in End Stage Renal Disease patients requiring hemodialysis. If there is no possibility of other access modalities, failed or unable to create native arteriovenous fistula (AVF), Permcath can be a very good alternative.

Objective

To find the indications, complications and results of Permcath insertion.

Method

We reviewed the results of 92 Permcath inserted under ultrasound guidance in two different hospitals, 45 in Sahid Dharma Bhakta National Transplant Center (SDNTC), Bhaktapur and 47 in Nidan Hospital Pvt. Ltd., Lalitpur from April 2016 to April 2018 retrospectively.

Result

We had inserted 55 Permcath (59.78%) in right internal jugular vein (IJV), 25 (27.17%) in left internal jugular vein and 12(13.04%) in femoral vein. In terms of major complications, two (2.17%) patients had profound hypotension, bradycardia and cardiac arrest due to left internal jugular vein tear. Three patients (3.26%) died within a week due to septicemia and 23 patients (25%) died with multiple causes within one year. Of the cases, till now in 39 cases (42.39%) Permcath has been removed. Major reasons of removal of Permcath are post renal transplant in 18 cases (19.57%), Arterio Venous Fistula maturation in 13 cases (14.13%), Infection in six patients (6.52%) and non functioning Permcath in two patients (2.17%).

Conclusion

Permcath remains a reliable method for short term vascular access, hence can be used as a bridge to renal transplant or arteriovenous fistula maturation.

KEY WORDS

Permcath, Tunneled dialysis catheter, Vascular access

INTRODUCTION

Native arteriovenous fistula (Brescia-Cimino) in the arm is gold standard and the first choice for the end stage renal disease patients who need long term hemodialysis.¹⁻³ When many patients before AV fistula creation or while waiting for AV fistula maturation require urgent hemodialysis it is better to use tunneled dialysis catheter Permcath (fig. 1).³ In addition, in some patients who have no suitable vessels for creation of an AV fistula, or in whom there have been multiple attempts failed, Permcath is an alternative form of long-term vascular access.^{4,5} Non-tunneled double lumen percutaneous internal jugular catheter widely used for short term temporary vascular access is generally satisfactory, but complications, principally infection and thrombosis, limit its usefulness. Subclavian route is associated with a high incidence of central venous thrombosis which may compromise future AV fistula in that extremity.⁴

We have been using the Permcath Chronic Silicone Oval Catheter, a double lumen tunneled dialysis catheter inserted under ultrasound guidance to minimize the risk of arterial puncture, hematoma and pneumothorax.

In this study we would like to explore the indication, sites of insertion, results and complication of Permcath insertion.

METHODS

Retrospective study was done in two different hospital, Shahid Dharmabhakta National Transplant Center (SDNTC), Bhaktapur and Nidan Hospital, Lalitpur, Nepal. We reviewed the results of 92 Permcath insertion from April 2016 to April 2018. We used 36cm in length for right and 40cm for left IJV. A Dacron felt cuff is situated in 19 cm and 23 cm from the tip respectively, serving to anchor the catheter in its tunnel by the growth of fibrous tissue. There are two parallel lumens, each with an internal diameter of 2 mm and priming volumes of 1.3 ml and 1.4 ml per lumen. The venous proximal lumen end is 2.5 cm away from the arterial end to minimize the recirculation. On the other side at the periphery of the catheter is a hub from which the channels diverge ending in color coded luer locks; red for arterial (out flow) and blue for venous (inflow) ports. There is attached clamp on each channel.⁵

The first choice for Permcath placement was mainly into the right IJV and the second choice was the left IJV if right IJV was thrombosed or stenosis following prior catheterization.⁶⁻⁹ If not possible or not suitable to insert both side then only we used femoral vein. Catheterization took place in the operating theater. The skin overlying the desired insertion site were washed, prepared and draped with sterile surgical cloth with patient in the supine position. In all cases Permcath was inserted under ultrasound guidance. The linear probe was used to show the vein and artery. After visualization of the carotid artery in the medial side and internal jugular vein in the lateral

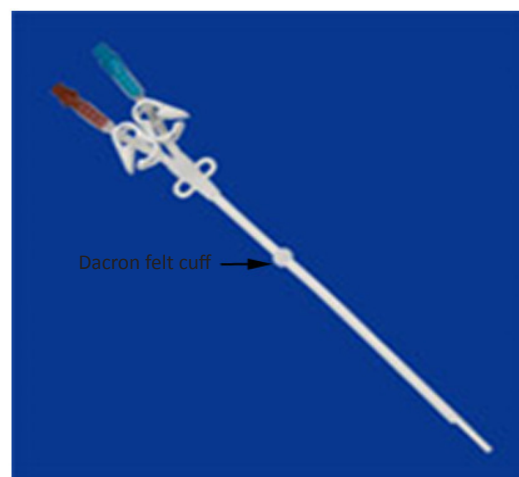


Figure 1. Showing Permcath.

position, the compressibility of the vein and the pulsatility of the artery, catheterization was performed with Seldinger method under local anesthesia. After local anesthesia under USG guidance, the Internal Jugular vein was punctured and guide wire pushed through the needle. Then the catheter is measured against the chest to estimate the distance to the right atrium. After local anesthesia a stab incision on skin is made near the deltopectoral groove or lateral to the mid clavicular line. Insertion of malleable probe subcutaneously creating a tunnel up to the internal jugular puncture site was done. Through the tunnel, Permcath was passed so that the cuff lies in the tunnel. The internal jugular vein was dilated with dilator through the guide wire. Permcath was inserted through the sheath after removing the oval dilator. Then the sheath was peeled followed by pushing the catheter toward the superior venacava.^{8,9} We never use blind technique for Permcath insertion so never had arterial puncture during catheterization. Sometime if any problem arise during procedure, we used C-arm fluoroscope to see the guide wire and Permcath. After hemostasis flow was checked in both arterial and venous port and flushed with heparin saline. Catheter was fixed with suture. All patients were checked by chest x-ray for position of the catheter and possible complications.

RESULTS

A total 92 patients, 45 from SDNTC and 47 from Nidan Hospital underwent Permcath insertion of which 46 (50%) were male and 46 (50%) were female. Mean age was 56.6years, SD 17, Range 18-85years. In 55 cases (59.78%) Permcath was inserted in right IJV, 25 (27.17%) in left IJV and 12 (13.04%) in femoral vein (table 1). Two patients immediately after Permcath insertion in left IJV developed hypotension, bradycardia and cardiac arrest, medicines and CPR were not effective in both cases. Most probable cause of death may be left IJV tear. Three patients died in ICU within a week due to septicemia, 12 with multi organ failure after 6 week and 11 died within one year with multiple causes.

Table 1. Showing number of Permcath insertion in different anatomical locations.

Anatomical locations	No and % of Patients	Side	Temporary catheter	Permcath
Internal jugular vein	80 (86.96)	Right	45	55
		Left	22	25
Femoral vein	12 (13.04)	Right	6	8
		Left	1	4
Total	92		74	92

Due to catheter dysfunction, multiple manipulation of Permcath was done in 12 (13.04%) patients within two to six weeks of hemodialysis and 16 (22.61%) after six weeks. Permcath was removed in total 39 (42.39%) patients: 18 post renal transplant, 13 after AVF maturation, six Permcath related infection and two due to non-functioning.

DISCUSSION

Permcath is better than temporary non-tunneled double lumen catheter but not the ideal form of long term vascular access for hemodialysis.⁵ When other modalities for dialysis is not available this can offer a very reliable alternative for dialysis access. In a study it was found that the median duration of functioning of Permcath is 105 days with 18% Permcaths functioning over a year.⁵ Initially the Permcath used to be placed under direct vision or by blind techniques but with availability of ultrasound more and more experts are placing it under ultrasound guidance. One of the most important finding of the present study was there was no incidence of arterial puncture under ultrasound guidance associated with the internal jugular vein and femoral vein cannulation. Use of ultrasound guidance for cannulation prevents accidental arterial puncture as ultrasound can very clearly differentiate the artery and the vein. Another important result is that Permcath should be used as temporary vascular access for

bridge to early renal transplant or waiting for AV fistula maturation, to prevent the stenosis or thrombosis of the central veins. In addition, some patients have no suitable vessels for creation of an AV fistula, or there have been multiple attempts failed, need an alternative form of long-term vascular access.⁸⁻¹⁰ In our study Permcath infections were due to Permcath insertion same side immediately after use of temporary non tunneled catheter and lack of knowledge about Permcath. Multiple manipulation and non functioning of Permcath were due to previous long duration use of temporary non tunneled dialysis catheter induced central venous stenosis and thrombosis.^{11,12} But more patients are being referred for long term access in the elderly and in patients where other access modalities are unavailable or have failed. In a study only 2% of newly placed tunneled dialysis catheters are in the femoral vein but in our study it comes to 13% due to frequent and long term use of non-tunneled dialysis catheter.¹³ Tunneled femoral vein dialysis catheters can be used as a final resort when all other options for a permanent vascular access or thoracic central vein catheter have been tried and not usable.

Adherence to guidelines of catheter related infections, prophylaxis, diagnosis and treatment can save lives. But above all, avoiding the use of central vein catheter is the best way to prevent infectious complications. It can be reached through early nephrologist referral and effort to preserve the veins of CKD patients, enabling proper timing of AVF creation, with its associated impact on morbidity and mortality in hemodialysis patients.¹⁴

CONCLUSION

The autologous AVF creation is the first choice in ESRD patients but Permcath remains a reliable method for temporary vascular access for hemodialysis. Permcath has valuable role during bridge period to renal transplant or waiting for AVF maturation. In elderly patient this can also be used as long term access.

REFERENCES

1. Biuckians A, Scott EC, Meier GH, Panneton JM, Glickman MH. The natural history of autologous fistulas as first-time dialysis access in the KDOQI era. *Journal of vascular surgery*. 2008 Feb 1;47(2):415-21.
2. Konner K, Nonnast-Daniel B, Ritz E. The arteriovenous fistula. *Journal of the American Society of Nephrology*. 2003 Jun 1;14(6):1669-80.
3. Konner K. History of vascular access for hemodialysis. *Nephrol Dial Transplant*. 2005;20:2629-35.
4. Edward C, Joanne K, Jennifer MR, Christine D, Swapnil H, Mercedes K, et al. Practical aspects of nontunneled and tunneled hemodialysis catheters. *Canadian Journal of Kidney Health and Disease*. 2016;3: 1-9.
5. Boyle MJ, Gawley WF, Hickey DP, Drumm J, Murphy DM, Hanson JS and Glacken P. Experience using the Quinton Permcath for haemodialysis in the Iris Republic. *Nephrol Dial Transplant*. 1997;12:1934-9.
6. Al-Wakeel JS, Malik GH, Al-Mohaya SA, Shareefi O, Mitwalli AH. Permcath as Temporary Vascular Access for Hemodialysis. *Vascular Surgery*. 1999;33(1):67-72.
7. Bagul A, Brook NR, Kaushik M, Nicholson ML. Tunneled Catheters for the Haemodialysis Patient. *Eur J Vasc Endovasc Surg*. 2007; 33: 105-12.
8. Aydin Z, Gursu M, Uzun S, Karadag S, Tatli E, Sumnu A, et al. Placement of hemodialysis catheters with a technical, functional, and anatomical viewpoint. *International journal of nephrology*. 2012;2012.
9. Wang P, Wang Y, Qiao Y, Zhou S, Liang X, Liu Z. A retrospective study of preferable alternative route to right internal jugular vein for placing tunneled dialysis catheters: right external jugular vein versus left internal jugular vein. *PLoS one*. 2016;11(1).

10. Budruddin M, Mohsin N, Amitabh J, Ehab M, Proamod K, Abbas P, et al. Femoral Vein Tunneled Catheters a a Last Resort to Vascular Access: Report of Five Cases and Review of Literature. *Renal Failure*. 2009;31:320-2.
11. Dilorio BR, Mondillo F, Bortone S, Nargi P, Capozzi M, Spagnuolo T, et al. Fourteen years of hemodialysis with a central venous catheter: mechanical long-term complications. *J Vasc Access*. 2006;7(2):60-5.
12. Gupta A, Karak PK, Saddekni S. Translumbar inferior Vena Cava Catheter for Long-Term Hemodialysis. *J Am Soc Nephrol*. 1995;5: 2094-97.
13. Maya ID, Allon M. Outcomes of tunneled femoral hemodialysis catheters: Comparison with internal jugular vein catheters. *Kidney International*. 2005; 68: 2886-9.
14. Bohlke M, Uliano G, Barcellos FC. Hemodialysis catheter-related infection: prophylaxis, diagnosis and treatment: *J. Vasc Access* 2015; 16(5):347-55.