

Oral Cysticercosis Presenting as an Innocuous Lesion

Marla V,¹ Makaju R,² Bhandari S,² Shrestha S,² Shrestha S,³ Shrestha KS,⁴ Srii R¹

¹Department of Oral Pathology,
Penang International Dental College,
Malaysia.

²Department of Pathology,

³Department of Internal Medicine

⁴Department of Otorhinolaryngology
Kathmandu University School of Medical Sciences,
Dhulikhel, Kavre, Nepal.

Corresponding Author

Ritesh Srii

Department of Oral Pathology,
Kathmandu University School of Medical Sciences,
Dhulikhel, Kavre, Nepal.

E-mail: ritesh3741@gmail.com

Citation

Marla V, Makaju R, Bhandari S, Shrestha S, Shrestha S, Shrestha KS, et al. Oral Cysticercosis Presenting as an Innocuous Lesion. *Kathmandu Univ Med J.* 2019;68(4):352-5.

INTRODUCTION

Parasitic zoonoses are a common cause of burden to public health in developing countries. These infections are acquired by humans, either by consumption of host or through the feaco-oral route.¹ A developing country like Nepal shows a significant risk of morbidity due to infectious diseases owing to its varied topography and socio-economic status. Nepal is known to be endemic for at least ten parasitic infections with cysticercosis being a cause of major concern.²

Cysticercosis is a parasitic infection which is primarily caused by the consumption of improperly cooked pork meat. Other ways of acquiring this infection is through contaminated vegetables, food and water. These sources contain the parasite *Taenia Solium* or its eggs which upon ingestion colonize in the small intestine.³ The gastric secretion dissolves the membrane of the eggs thereby releasing the larvae which penetrates the intestinal mucosa and gains entry into the systemic circulation. The larvae then lodges

ABSTRACT

Cysticercosis is a parasitic infection with potential of causing significant morbidity especially in developing countries. The larval form of the parasite *Taenia Solium*, 'Cysticercus Cellulosae' primarily colonizes in the small intestine and has the potential to disseminate to different sites of the body. Oral presentation is rare and difficult to detect owing to its innocuous presentation. This report describes the presentation of cysticercosis involving the tongue and presenting as a submucosal mass. An incisional biopsy was performed and evaluation of the histopathological features lead to the diagnosis of oral cysticercosis. This article highlights the importance of inter-departmental collaboration for the accurate diagnosis and effective management of oral cysticercosis in order to avoid potential systemic complications.

KEY WORDS

Cysticercosis, Histopathology, Oral cavity, Parasite, Systemic complications

in a distant tissue, preferably muscles or subcutaneous tissue resulting in an active infection which is known as cysticercosis.⁴ A potentially serious manifestation of the disseminated form of cysticercosis is neurocysticercosis which can be life threatening. Cysticercosis is endemic in different parts of the world including Latin America, Asia and Africa.⁵

Oral Cysticercosis is a relatively uncommon form with over hundred cases reported in the English literature. The lesion usually manifests as a small nodular growth with tongue being the most common intra oral location. Because of its benign nature, histopathological evaluation may be neglected following excision especially in countries with limited resources.⁶ This case report describes the presentation of cysticercosis of the tongue with an innocuous presentation and the role of histopathological evaluation in its identification thereby avoiding further complications.

CASE REPORT

An 18 years old male patient reported to the outpatient department with chief complaint of a painless nodular growth on the ventral surface of the tongue of 2 weeks duration. The nodule was slow growing and measured approximately 1x1 cm in greatest dimension; was soft to firm in consistency. The growth was evident near the midline of the tongue. The patient had mixed dietary habits with frequent consumption of food at restaurants. Patient did not have any significant medical history and there was no past incidence of irregular bowel habits. Based on the clinical findings, a provisional diagnosis of Dermoid cyst of the tongue was considered. An excisional biopsy was performed and the specimen was submitted for histopathological evaluation.

Microscopic examination revealed a small cystic lumen in the lamina propria which was lined by fibrous connective tissue capsule. The cystic cavity revealed cysticercus cellulosae (fig. 1) which was lined by a bilaminar membrane composed of an outer acellular hyaline layer and an inner acellular eosinophilic layer showing degenerative changes (fig. 2). The bladder wall of the larva showed a light eosinophilic wavy membrane. Focal areas within the bladder showed specks of calcification (fig. 3). The cystic capsule revealed dense chronic inflammatory cell infiltration composed of eosinophils, lymphocytes and macrophages. The overlying epithelium was spongiotic and parakeratinized. The submucosa revealed muscle and nerve fibers; acini and ducts of minor salivary glands. Differential leukocyte count was performed which revealed 26% of eosinophils suggestive of eosinophilia. Based on these findings, a diagnosis of Oral Cysticercosis was given. Following diagnosis, the patient was treated by a dose of 400 mg Albendazole, twice daily for three weeks along with a regularly tapered dose of Dexamethasone.

DISCUSSION

Cysticercosis is a parasitic infection which was first described in 1955 by a physician, Johannes Udalric Rumler.⁷ It is described as endemic in various parts of the world including Africa, Latin America and parts of Asia including Nepal. The endemic status is mainly due to the low predominant low socio-economic status within the country, vast farmlands and a mixed dietary pattern of the population including consumption of pork.² The infection is caused by the larval form of the parasite *Taenia Solium* which is known as cysticercus cellulosae. The parasite spends its lifetime in different hosts and is characterized by various developmental stages including proglottids (eggs), oncospheres, larval stage and the adult form.⁸ Pigs and humans act as hosts for *Taenia solium*. Humans being both the definitive host and intermediate host. The parasite or larvae may gain entry in humans through improperly cooked pork, following which it colonizes in the intestine.

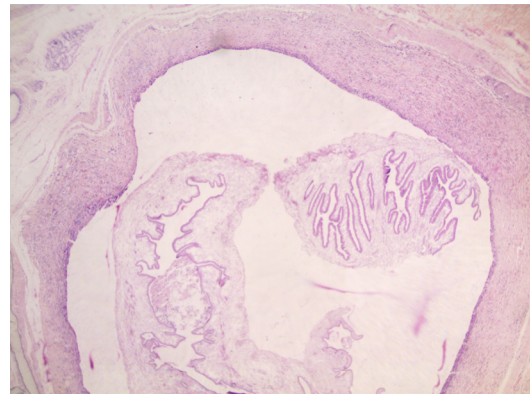


Figure 1. Cystic space within connective tissue showing cysticercus cellulosae (H&E, 40x)

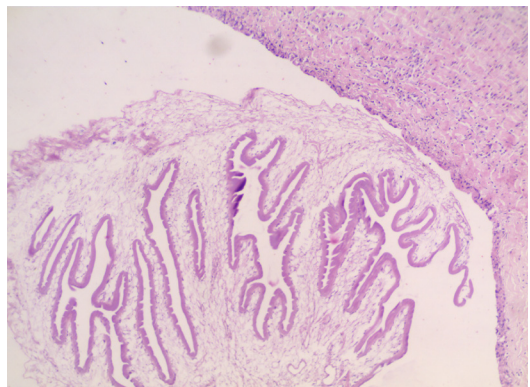


Figure 2. Eosinophilic bilaminar membrane of cysticercus cellulosae (H&E, 100x)

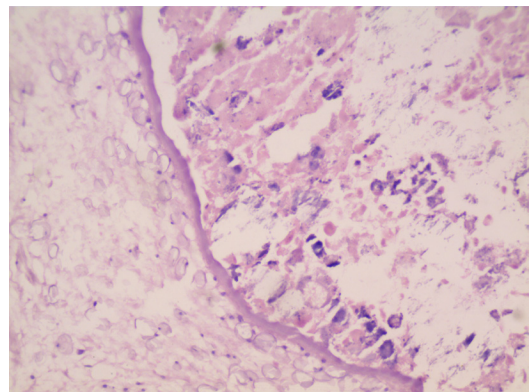


Figure 3. Dystrophic calcification within the larva (H&E, 400X)

The larva develops into the adult form and continues to colonize in the intestine. In such instances, humans act as a definitive host.⁹ The term Taeniasis is given when the larva completes its life cycle within the human body to transform into an adult form.¹⁰ The adult worm can reside within the humans for years and lay nearly thousand eggs.³

Alternately, the eggs may be ingested through the feaco-oral route through contaminated vegetables or meat. In such a scenario, humans serve as an intermediate host and poses serious clinical implications. The humans act as carriers or develop active infection due to systemic dissemination of the eggs or oncospheres resulting in Cysticercosis of different organs or tissues.⁴ The oncospheres are released from the eggs upon dissolution by the gastric secretions

following which the larva penetrate the intestinal mucosa and gain entry into the vascular and lymphatic circulation. The larva gets lodged in muscles and subcutaneous tissue, with preferential locations being brain, heart, liver, lungs, peritoneum and the oral cavity.¹¹

Oral cysticercosis is a relatively uncommon lesion and shows a prevalence of 4.1%.¹² One study has reported the incidence of oral cysticercosis to be 1.8% with even lower incidence in paediatric population.¹¹ Tongue is the most common intra-oral location and usually presents as a solitary nodular growth in the subcutaneous or muscular tissue.¹³ Our case also showed the presentation of cysticercosis as a painless nodular growth on the ventral aspect of tongue. Multiple growths presenting as oral cysticercosis have also been reported.¹⁴ Other intra-oral locations are lips, particularly the lower lip followed by the buccal mucosa.¹³ The nodular growths are generally firm on palpation and this is due the raised intra-luminal pressure within the cystic cavity. The lesions are usually asymptomatic because the live parasites are well tolerated in the tissues.² This causes a diagnostic dilemma clinically and are usually confused as mucocele, fibroma, pyogenic granuloma or other benign mesenchymal/salivary gland neoplasm.^{7,13} Cases have also been reported involving the muscles of mastication resulting in reduced mouth opening. Such cases are detected incidentally following imaging studies.¹⁵ Pain has been reported following the degeneration of the microorganism which evokes an inflammatory reaction within the tissue.⁸ Oral cysticercosis represents a disseminated form of the infection and should be carefully evaluated for lesions in other sites to avoid potential systemic complications.⁹ However, such instances have not been reported in the literature. The intensity of signs and symptoms have also been said to be dependent on the number of oncospheres within the tissue and also on its specific anatomic location with symptoms varying accordingly.¹¹

Among the other forms of disseminated cysticercosis, cerebral involvement has the most serious implication. The condition is referred to as Neurocysticercosis and presents with variable signs and symptoms including headaches, meningitis, increased intracranial pressure, acute obstructive hydrocephalus and epileptic seizures. It has also been noted that it is the most common cause of acquired epilepsy in the developing countries.² Neurocysticercosis has also been implicated in the development of certain neoplasms like cerebral gliomas, astrocytomas and few malignant haematological diseases. Few hypothesis put forward suggests that genetic material of the parasite may result in chromosomal aberrations within the host leading to the development of neoplasms. Other theories suggest that persistent chronic inflammatory reaction may inhibit the immunological surveillance leading to malignant transformation of the localized tissues.¹⁶ Ocular

involvement of cysticercosis may result in glaucomas and iridocyclitis; whereas involvement of the heart may cause cardiac arrhythmias. Other symptoms of cysticercosis have been described as fever and myalgias.^{10,11}

Various diagnostic modalities have been utilized for the identification of cysticercosis including haematological, biochemical, imaging, histopathology and genetics.⁹ A blood picture in a patient reveals elevated eosinophilic count suggestive of parasitic infection. This was the case in this patient where eosinophilia was detected. Imaging studies like computerized tomography (CT), magnetic resonance imaging (MRI) and sonography have been utilized in detecting cysticercosis especially in cases on cerebral involvement.⁵ One report described the role of sonography in identifying the lesion in case of masseteric muscle involvement.¹⁵ Small superficial lesions are usually biopsied and subjected to histopathological evaluation. This is the case for lesions involving the oral cavity because they are easily accessible for surgical exploration as was observed in our case.² Histopathology clearly aides in the identification of the larva, *Cysticercus cellulosae* thereby giving a confirmatory diagnosis. Also it is possible to suggest if the organism is still active or degenerated.⁸ Our case was suggestive of a degenerative larva due to the absence of inner cellular layer and also due to the presence of dystrophic calcification. Few reports have also highlighted the role of fine-needle aspiration in the diagnosis of cysticercosis.¹⁷ Stool samples have also been analysed for identification of the parasite. Other advanced diagnostic techniques include immunodiagnosis by either enzyme-linked immunosorbent assay (ELISA) or enzyme-linked immunoelectrotransfer bolt (EITB).⁹

Treatment of oral cysticercosis generally includes surgical excision and/or therapeutic management. Oral lesions are generally superficial nodules and easily excised except in cases where the larvae are lodged in deeper areas like in case of masseter.^{2,15} Medications include a combination of albendazole and systemic corticosteroids. Albendazole causes the death of the parasite which elicits a reactive inflammatory reaction and corticosteroids are given to suppress this untoward reaction. The dose of corticosteroids is tapered towards the end of the treatment schedule. Medical management also eliminates any residual disseminated infection in other parts of the body.^{8,10,13}

Oral cysticercosis are relatively uncommon lesions and may pose a diagnostic difficulty due to the benign nature of the localised lesion. However, it represents a disseminated form of the parasitic infection. Other disseminated forms may pose serious complications. Oral Cysticercosis should be considered as a possible differential diagnosis by the clinicians especially in endemic regions like Nepal.

REFERENCES

1. Devleeschauwer B, Ale A, Torgerson P, Praet N, Maertens de Noordhout C, et al. The Burden of Parasitic Zoonoses in Nepal: A Systematic Review. *PLoS Negl Trop Dis*. 2014; 8(1): e2634. doi:10.1371/journal.pntd.0002634
2. Rajshekhar V. Epidemiology of Taenia Solium taeniasis and cysticercosis in India and Nepal. *Southeast Asian J Trop Med Public Health*. 2004; 35(1): 247-51.
3. Hosur MB, Byakodi S, Puranik RS, Vanaki SS, Puranik SR, Shivakumar MS. Oral Cysticercosis: A Case Report and Review of Literature. *Journal of Maxillofacial & Oral Surgery*. 2015;14(3):853-7. doi:10.1007/s12663-015-0745-x.
4. Elias FM, Martins MT, Foronda R, Jorge WA, de Araújo NS. Oral cysticercosis: case report and review of the literature. *Rev Inst Med trop S Paulo*. 2005; 47(2):95-8.
5. Rizvi SA, Saleh AM, Frimpong H, Al Mohiy HM, Ahmed J, Edwards RD, Ahmed SS. Neurocysticercosis: a case report and brief review. *Asian Pac J Trop Med*. 2016, 9 (1): 100-2.
6. Devulapalli RV, Bangi BB, Nadendla LK, Pokala A. Oral cysticercosis: A rare case presentation with ultrasound and MRI findings. *J Indian Acad Oral Med Radiol*. 2015; 27: 322-6.
7. Joshi J, Sharanasha MB, Jatwa R, Khetrpal S. Oral Cysticercosis: A Diagnostic Difficulty. *Journal of Clinical and Diagnostic Research : JCDR*. 2014; 8(10):ZD24-ZD25. doi:10.7860/JCDR/2014/10278.5024.
8. Chunduri NS, Goteki V, Gelli V, Madasu K. Oral Cysticercosis. *Southeast Asian J Trop Med Public Health*. 2013; 44(2): 154-6.
9. Rao SC, Sharma H, Vinay KN, Vidya KC. Oral cysticercosis – A case report. *Int J Clin Dent Sci*. 2011; 2(4): 36-9.
10. Gupta K. Oral cysticercosis. *Indian J Sci Res*. 2017; 15 (1): 95-6.
11. Goenka P, Sarawgi A, Asopa K, Gumber P, Dutta S. Oral Cysticercosis in a Pediatric Patient: A Rare Case Report with Review. *Int J Clin Pediatr Dent*. 2016; 9(2):156-161.
12. Bhatia VO, Natekar AA, Valand AG. Paediatric Oral Cysticercosis: A Misdiagnosed and a Rare Entity. *International Journal of Oral & Maxillofacial Pathology*. 2014;5(2):26-28.
13. Kulkarni PG, Palakurthy P, Muddana K, Nandan RK. Oral Cysticercosis- A Diagnostic Dilemma. *Journal of Clinical and Diagnostic Research : JCDR*. 2015; 9(6):ZD01-ZD02. doi:10.7860/JCDR/2015/11759.6044.
14. Jay A, Dhanda J, Chiodini PL, Woodrow CJ, Farthing PM, Evans J, Jager HR. Oral cysticercosis. *Br J Oral Maxillofac Surg*. 2007; 45(4):331-4. doi: 10.1016/j.bjoms.2005.09.014.
15. Bhat V, Nagarjuna M, Belaval V, Shetty S, Salins PC. *Dentomaxillofac Radiol*. 2015; 44(7):20150133.
16. Wanjari SP, Patidar KA, Parwani RN, Tekade SA. Oral cysticercosis: A clinical dilemma. *BMJ Case Rep*. 2013. doi:10.1136/bcr-2012-007482.
17. Fernandez RL, Rodríguez JT, Carrasco-Daza D, Sotelo-Morales J, Mosqueda-Taylor A. Oral cysticercosis in the paediatric patient: Report of six cases. *Rev Esp Cir Oral Maxillofac*. 2016; 39(1): 33-36.