

C-ARM Guided Angiogram/Angioplasty for Selected Failed Arterio Venous Fistula. A Report of a Procedure at University Hospital of Nepal

Vaidya S,¹ Karmacharya RM,¹ Singh AK,¹ Vaidya PR,² Malinowski M,³ Dhakal A¹

¹Department of Surgery (Cardio Thoracic and Vascular Surgery)
Dhulikhel Hospital, Kathmandu University Hospital,
Dhulikhel, Kavre, Nepal.

²Consultant (Cardio and Vascular Surgery),
KIST Medical College Teaching Hospital,
Gwarko, Lalitpur.

³Consultant (Medical College of Wisconsin)
Wisconsin, USA.

Corresponding Author

Satish Vaidya

Department of Surgery (Cardio Thoracic and Vascular Surgery)

Dhulikhel Hospital, Kathmandu University Hospital,
Dhulikhel, Kavre, Nepal.

E-mail: satish.vaidya.nep@gmail.com

Citation

Vaidya S, Karmacharya RM, Singh AK, Vaidya PR, Malinowski M, Dhakal A. C-ARM Guided Angiogram/Angioplasty for Selected Failed Arterio Venous Fistula. A Report of a Procedure at University Hospital of Nepal. *Kathmandu Univ Med J.* 2021;75(3):399-401.

INTRODUCTION

End Stage Renal Disease (ESRD) is defined as the last stage of Chronic Kidney Disease (CKD) which is characterized by Glomerular Filtration Rate of less than 15 ml/min/1.73 m².¹ Renal Replacement Therapies (RRT) are the common modalities for the treatment of patients with ESRD, before kidney transplantation. Hemodialysis is the most commonly used modality of RRT worldwide.² Arteriovenous Fistula (AVF), Arteriovenous Graft (AVG) and Central Venous Catheter (CVC) are three main types of vascular access for application of hemodialysis.³ Out of these, AV fistula is the most preferred method of vascular access in those undergoing Hemodialysis as they have decreased risk of infection in comparison with AVGs and are more durable.⁴ However, one of the common problems of AVF is significant stenosis (> 50% of lumen) which is usually restored with Percutaneous Transluminal Angioplasty (PTA) or surgical

ABSTRACT

End Stage Renal Disease is a last stage of Chronic Kidney Disease which is characterized by Glomerular Filtration rate of less than 15 ml/min/1.73 m². Hemodialysis is the most commonly used modality for treatment of Chronic Kidney disease. Among the access for hemodialysis arteriovenous fistula is the most common modality. However most common problems of fistula are significant stenosis of more than 50% which is characterized by limb swelling, pigmentation, tortuous veins, and difficulty maintaining flow during dialysis from AV fistula. These can be managed either by minimal intervention or with surgical intervention. Very few hospitals in Nepal and other countries have an angiographic suite to perform minimal intervention include angiogram with angioplasty. So in this case we try to address the use of C-Arm to perform angiogram or fistulogram and even angioplasty for the management of significant stenosis or complications of arteriovenous fistula.

KEY WORDS

Angiogram/Angioplasty, Arterio venous fistula, C-arm

intervention.⁵ Imaging modalities that have been commonly used in identifying and mapping of vascular access and their lesions are Ultrasound (USG), Angiography, and Computed Tomography Angiography (CTA).⁶ Physical exam, along with ultrasonography are the mainstays for the assessment of a nonmaturing or failing vascular.

Stenosis in an AVF is the most common reason that an AVF will fail to mature with the incidence ranging from 20 to 60 percent. The most common sites for stenosis leading to failure of maturation include juxta-anastomotic location 55%, body of fistula 29%, peripheral draining veins 10% feeding artery 6%.⁷

The development of stenosis in the Vascular access can also occur over time with its use. Stenosis in an AVF can occur at the juxta-anastomotic site as well as various sites

within the venous segment and tends to occur where there is increased turbulence.⁸ Common sites of stenosis along the venous portion of the AVF include sites where the access is frequently cannulated, swing points, valves and areas of branching.⁹

Central vein stenosis can occur and is frequently due to the patients having had central catheters for dialysis access, pacemakers or other interventions that require access of central veins which in turn can jeopardize functioning of an AV fistula.¹⁰ This is characterized in involved limb by swelling, pigmentation, tortuous veins, and difficulty maintaining flow during dialysis from AV fistula.

The purpose of this case report is to introduce the concept of using a C-arm, and to perform a diagnostic study and assist in the modality of balloon angioplasty C-arm guided PTA in the restoration to restore of patency of stenotic AV fistulas. Technically in C-arm guided PTA, the luxury of road mapping, three dimensional reconstruction and rapid change in position is not as good as in a cardiac catheterization laboratory. set-up.

We hereby present our case of C-arm guided angiography with angioplasty done at The Kathmandu University Hospital of Nepal. The general preparation and setup of equipment is also explained in this series.

CASE REPORT

A 38 years old male was referred to our center with a history of right arm swelling for the last 4 months. He had developed ESRD secondary to hypertensive nephropathy. The patient had received regular dialysis for two years via his right radio cephalic fistula after which it became dysfunctional. He then underwent creation of a right upper arm brachiocephalic AV fistula 3 years ago. The fistula had been working well, however over the last 4 months, he started to have difficulty in maintaining good flow during dialysis and also developed the associated arm swelling. Doppler ultrasonography showed a good anastomosis between the brachial artery and cephalic vein with a diameter of 4 mm and flow of 450 cm/s. The cephalic vein in the upper arm at the level of distal forearm was also of good diameter (6 mm). The cephalic vein, at the level of the arch, was just 4 mm in diameter and just distal to the axillary vein, the subclavian vein looked to have a diameter of 4 mm. We recognize that the majority of times it is difficult to see the subclavian vein with ultrasound, but our findings supported the need for a fistulogram to further assess the vascular access and potentially do a therapeutic intervention.

Figure 1 shows a stenosis in the cephalic arch and subclavian vein. The stenosis in the cephalic arch was not felt to be significant nor contributing to the patient's arm swelling.

After confirming the stenosis sites, a microguidewire of size 0.014 diameter of length 80 cm was inserted via the access

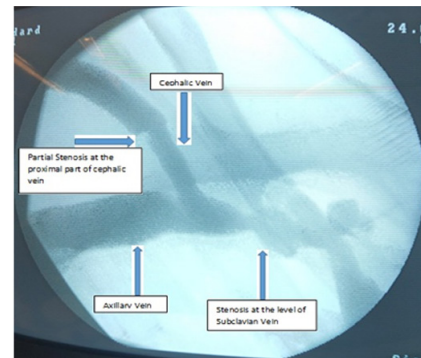


Figure 1. Stenosis at the level of right subclavian vein.

needle. This was confirmed with the help of C-arm. The guidewire was then exchanged with J curve soft tip catheter which was then negotiated up to the superior vena cava proximal to the stenosis at the level of subclavian vein. A balloon of 4 cm length and diameter of 6 mm was inserted with the final position of the balloon across the stenosis confirmed by C-arm as shown in figure 2. The balloon was inflated using a graduated inflator. The pressure was maintained at the level of 3 atm pressure for 3 minutes.

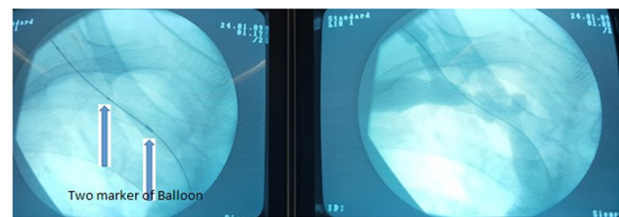


Figure 2. Markers of the balloon of length 4 cm and diameter of 6mm being positioned across the stenosis. I do not believe you need the photo on the right.

During balloon dilatation, there was minimal residual wasting (fig. 3). The increase in diameter of vein was felt to be satisfactory. On the completion fistulogram, there was rapid washout of the contrast with an adequate increase in the diameter of the subclavian vein (fig. 3).

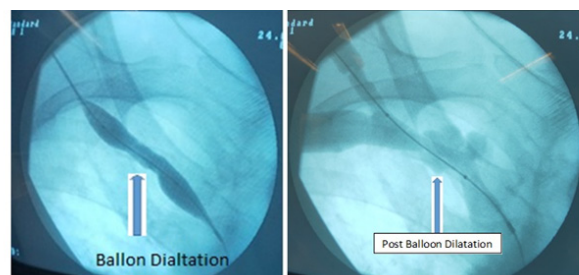


Figure 3. Residual wasting the stenosis site

At the time of his follow up visit, his arm swelling had reduced significantly and he had good flow in his AVF. At his four month follow up visit he continued to have good flow in his fistula and has not had recurrent arm swelling.

DISCUSSION

The maintenance of vascular access in renal failure patients is critical for their survival. It is not unusual for the access to not mature or develop problems after creation or use. Most times, the etiology of failure of an access can be determined by physical exam and ultrasound. On occasions it is desirable to have a fistulogram to assist in the determination of failure and plan for intervention. Very few hospitals in Nepal and other countries have an angiographic suite to perform a fistulogram. Many hospitals do have

standard radiographic equipment, or a C-arm, with which they can study a vascular access. We present here a case of using a c-arm to not only provide radiographic evidence of why an access is failing, but also using the technology to perform an angioplasty of the subclavian vein where operative intervention is not possible.

Use of a C-arm for an angiogram, with or without angioplasty, is a suitable alternative in case of unavailability of Cath Lab or angiography suite in the evaluation of a failing vascular access.

REFERENCES

1. Levey AS, Eckardt K-U, Tsukamoto Y, et al. Definition and classification of chronic kidney disease: A position statement from Kidney Disease: Improving Global Outcomes (KDIGO). *Kidney International*. 2005; 67: 2089-100.
2. Grassmann A, Gioberge S, Moeller S, et al. ESRD patients in 2004: global overview of patient numbers, treatment modalities and associated trends. *Nephrology Dialysis Transplantation*. 2005; 20: 2587-93.
3. Santoro D, Benedetto F, Mondello P, et al. Vascular access for hemodialysis: current perspectives. *International Journal of Nephrology and Renovascular Disease*. 2014; 281.
4. Bountouris I, Kritikou G, Degermetzoglou N, et al. A Review of Percutaneous Transluminal Angioplasty in Hemodialysis Fistula. *International Journal of Vascular Medicine*. 2018; 2018: 1-5.
5. Clinical Practice Guidelines for Vascular Access. *American Journal of Kidney Diseases*. 2006; 48: S176–S247.
6. Murphy EA, Ross RA, Jones RG, et al. Imaging in Vascular Access. *Cardiovascular Engineering and Technology*. 2017; 8: 255-72.
7. Allon M, Robbin ML. Increasing arteriovenous fistulas in hemodialysis patients: Problems and solutions. *Kidney International*. 2002; 62: 1109-24.
8. Sivanesan S. Sites of stenosis in AV fistulae for haemodialysis access. *Nephrology Dialysis Transplantation*. 1999; 14: 118-20.
9. Falk A, Teodorescu V, Lou WYW, et al. Treatment of ?swing point stenoses? in hemodialysis arteriovenous fistulae. *Clinical Nephrology*. 2003; 60: 35-41.
10. Mehta HJ. Central Venous Stenosis: What Should a Nephrologist Know? *Indian J Nephrol*. 2017; 27: 427-9.