

Penile fracture presenting as eggplant deformity

Tiwary SK¹, Singh MK², Khanna R³, Khanna AK

¹Senior Resident in Surgery, ²Resident in Surgery, ³Reader in Surgery, ⁴Professor of Surgery, Department of General surgery, Institute of Medical Sciences, Banaras Hindu University

Abstract

Penile fracture is caused by sudden trauma to erect penis leading to tear of corpora cavernosa. Although penile fracture is a rare condition, it can lead to crippling penile deformity and erectile impotence, if intervention is delayed. We describe a case of penile fracture caused by masturbation and satisfactory outcome after early surgical intervention. Usually only clinical assessment is sufficient for diagnosis.

Key words: Penis, Fracture, Prognosis.

Penile fracture is an uncommon urological emergency. Study of less than 1500 cases has been reported in literature from 1935 to 2005. Penile fracture needs immediate surgical intervention without delay and only clinical judgment is sufficient enough for guiding management. We present a case of penile fracture presenting as eggplant deformity¹ and satisfactory outcome after surgery. Immediate exploration and repair of cavernosal tear is essential for good prognostic outcome in cases of penile fracture.

Case report

A young male 17 years old came to surgical emergency with swelling, deformity and ecchymosis of penis since 24 hours. The patient gave a history of masturbation and manipulation of erect penis during early morning hours followed by a popping sound, pain and immediate detumescence. Pain was followed by swelling which was progressive and later on followed by ecchymosis. Patient was able to micturate normally without pain or haematuria.

On clinical examination, penis was ecchymosed, deformed and swollen with typical eggplant

deformity (Fig 1) that is highly diagnostic of penile fracture. Corporal defect was not palpable due to haematoma and swelling. Rolling sign was present in which clot over lateral aspect of left cavernosa was felt as firm, mobile, discrete swelling over which penile skin could be rolled.

On the basis of history and clinical examination, penile fracture was diagnosed. Only other condition that can be mimicked clinically is rupture of dorsal veins of penis which also requires surgical intervention. So surgery we planned. Degloving of penis was done through subcoronal circumferential incision. After incising buck's fascia, haematoma (3 cm X 2 cm) was exposed on lateral aspect of left cavernosa. After removal of haematoma, tunica albuginea tear of size 1 cm X 0.5 cm was exposed (Fig 2) which was repaired by Prolene 3-0 with interrupted sutures an inverting the knots inside. After closure of tunica albuginea tear, Buck's fascia was closed with Vicryl 3-0 followed by dartos fascia and skin closure with Prolene 3-0. Patient voided urine easily after 4 hours of surgery. Patient was kept on diazepam postoperatively to avoid penile erection. He was discharged on post-operative day 6.

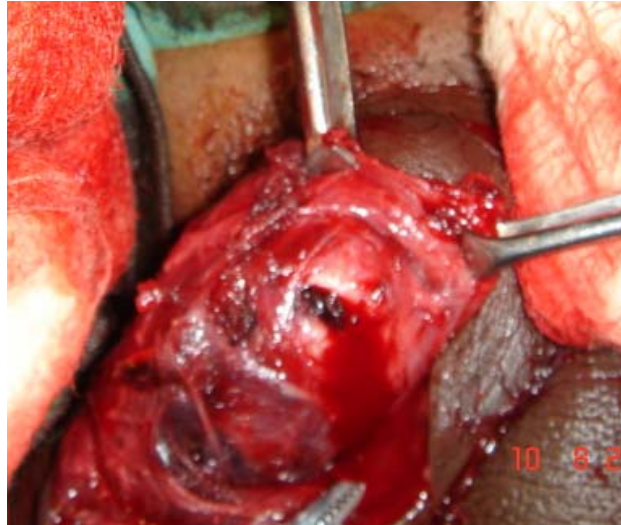
Correspondence

Prof A K Khanna
Department of General Surgery
Institute of Medical Sciences,
Banaras Hindu University, Varanasi
U.P.-221005
Email: akk_dr@sify.com

Fig 1: Eggplant deformity in fracture penis

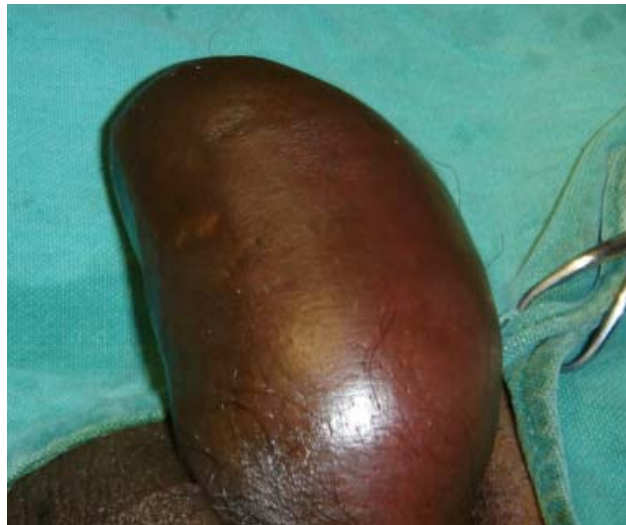

Fig 2: Tunica albuginea tear



Discussion

In Western countries, cause of penile fracture in most cases is strike of erect penis against symphysis pubis or perineum after slippage of penis out of vagina during intercourse². In Middle East countries penile fracture is more common than Western world and cause in most cases is self inflicted manipulation and injury during masturbation. Other causes of penile fracture are sudden bending of erect penis, falling on erect penis, being struck in penis, rolling over in bed or very rarely blow to flaccid penis during sports.

Only clinical examination with classical history is diagnostic. Investigations usually to be done are-Colour Doppler Ultrasound, MRI (for dorsal vein rupture), urethrography (for urethral injury), cavernosography. Only differential diagnosis is rupture of dorsal veins of penis. Both penile fracture and rupture of dorsal veins of penis require surgical exploration and repair as there is no role for conservative treatment.

Urethral injuries are associated with penile fracture in 38% cases and haematuria in 20% cases. So difficulty in voiding and haematuria should be investigated with urethrography and urethral repair should be done simultaneously with penile fracture. Tunical rupture may range from 0.5 cm to 5 cm^{1,3}. Primary repair with non-absorbable sutures with buried knots inside is preferable due to case reports of refracture

of penis repaired with absorbable sutures⁴. Cavernosal patch graft may be used for large tears.

Non-operative management leads to unacceptable deformity, prolonged hospitalization, pulsatile haematoma, residual penile mass, pulsatile cavernosal diverticulum, and expanding penile hematoma⁵. Thus early exploration with evacuation of haematoma followed by repair of cavernosal tear should be done in suspected penile fracture cases. Urethra injury should be evaluated and managed simultaneously.

References

1. Zargooshi. Penile fracture in Karmanshah, Iran: Report of 172 cases. *J Urol.* 2000; 164: 364-366.
2. Fegany AF, Angermier KW, Monntague DK: Review of Cleveland Clinic experience with penile fracture. *Urology* 1999; 54: 352-355.
3. Kardeniz T, Topaskal M, Ariman A, et al. Penile fracture: Differential diagnosis, management and outcome. *Br J Urol* 1996; 77: 279-281.
4. Prasanna GV, Khanna R, Khanna AK. Refracture Penis. *Case Rep Clin Pract Rev* 2003; 4 : 2-3.
5. Kalash SS, Young JD Jr. Fracture of penis: controversy of surgical versus conservative treatment. *Urology* 1984; 24: 21-24.