VOL. XX | NO. X | ISSUE XX | ....-.... (ONLINE FIRST-2018)

Full Coverage Crowns and Resin-bonded Bridge Combination for Missing Mandibular Anterior Teeth

Rokaya D, Mahat Y, Sapkota B, KC Basnyat S

Department of Dentistry

Kathmandu University School of Medical Sciences,

Dhulikhel, Kavre, Nepal.

Corresponding Author

Dinesh Rokaya

Department of Dentistry

Kathmandu University School of Medical Sciences,

Dhulikhel, Kavre, Nepal.

E-mail: dineshrokaya115@hotmail.com

Citation

Rokaya D, Mahat Y, Sapkota B, KC Basnyat S. Full Coverage Crowns and Resin-bonded Bridge Combination for Missing Mandibular Anterior Teeth. *Kathmandu Univ Med J.* Online first-2018.

ABSTRACT

Most often the anterior teeth and those that are visible when a patient speaks or smiles are chosen for esthetic restorations. The mandibular anterior fixed bridge often presents problems to the dentist due to the size of the natural teeth and their visibility. In addition, due to high cost factor, many patients are not able to afford fixed partial denture for missing anterior teeth. This article describes a cost effective technique for the restoration of missing mandibular anterior teeth by fabrication of full coverage crowns and resin-bonded fixed bridge combination.

KEY WORDS

Crown, Mandibular anterior teeth, Resin-bonded bridge

INTRODUCTION

Most often the anterior teeth and those that are visible when a patient speaks or smiles are chosen for esthetic restorations. Fixed bridge prosthesis is inserted permanently and worn by the patient in contrast to the removable type which may sometimes be discarded by the patient for no apparent reason.[1] Even though they restore the damaged, nonfunctional teeth to proper function and esthetics, the mandibular anterior fixed bridge often presents problems to the dentist due to small teeth size and their visibility.[2]

Porcelain-fused-to-metal (PFM) conventional bridge and resin-bonded bridge (Maryland bridge) have been popular and most heavily used restorations in dentistry over many decades of good clinical success. This clinical report presents a cost effective technique for fabrication of full coverage crowns and resin-bonded bridged combination for mandibular anterior missing teeth.

CASE REPORT

A 36-year-old female presented to the prosthodontic department with a chief complaint of missing lower anterior teeth and esthetic problem. Nothing relevant medical history was reported. She was using maxillary removable acrylic partial denture for 5 years and she was not satisfied with it and wanted fixed prosthesis. On intraoral examination, she had missing #31 and #41 (fig. 1-3). In addition, #32 and #42 showed grade I mobility. Maxillary arch was fully edentulous and has no any complaint (fig. 2). On intraoral periapical radiograph (IOPA), it revealed moderate bone loss around teeth #31 and #41 (fig. 3). The patient wanted fixed prosthesis without much altering her remaining teeth and couldn't afford expensive prosthetic treatment. She was given different treatment options with costs, advantages and limitations. She was happy to accept the treatment plan which consisted fabrication

Figure 1. Intraoral (labial) view showing missing #31 and #41.

Figure 2. A, Occlusal view of the intact maxillay arch. B, Occlusal view of the mandibular arch showing missing #31 and #41.

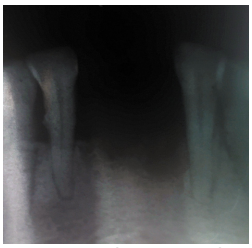

Figure 3. Intraoral periapical radiograph of the lower anterior teeth showing missing #31 and #41and bone loss around #32 and #42.

Figure 4. A, Labial view showing prepared teeth #33 and #43 for full coverage crowns. B, Occlusal view showing prepared teeth #33 and #43 for full coverage PFM crowns and prepared tooth for metal wings lingually in #32 and #42.

of full coverage FPM crowns in teeth #33 and #43 and resin-bonded bridge in teeth #31 and #41. The detailed procedure was explained to the patients.

Clinical and laboratory steps in the fabrication of the bridge:

1. Teeth #33 and #43 were prepared for the full coverage PFM crowns and, teeth #32 and #42 were prepared palatally for the resin-bonded metal wings (Fig. 4).

Figure 5. Final impression of the lower arch made with putty and light bodied polyvinyl siloxane.

Figure 6. Metal substructure of full coverage PFM crowns and resin-bonded bridge.

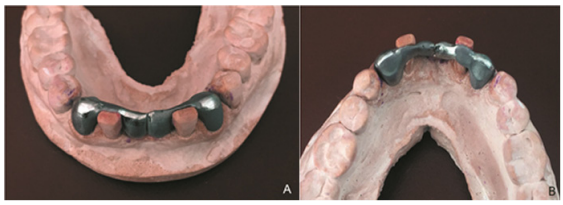

Figure 7. A, Labial view of metal substructure in cast. B, Occluso-lingual view of metal substructure in cast.

2. Final impression was made of the lower arch with putty and light bodied polyvinyl siloxane (Express; 3M ESPE, ST. Paul, Minnesota, USA) (fig. 5), it was poured with Type IV dental stone (Lafarage; Prestia, Meiel, France) to fabricate working model.

3. Metal substructure of full coverage crowns and resin-bonded bridge was fabricated (fig. 6-7), tried in patient's mouth. It was checked for the fit, adaptation and space for the ceramic. Shade selection was done.

4. After fabricating full coverage PFM crowns and resin-bonded bridge combination (fig. 8-9), it was tried in patient's mouth for the fit, adaptation, esthetic and occlusion. Necessary adjustments were done.

Figure 8. Full coverage PFM crowns and resin-bonded bridge combination.

Figure 9. A, Labial view of full coverage PFM crowns and resin-bonded bridge combination in cast. B, Occluso-lingual view of full coverage PFM crowns and resin-bonded bridge combination in cast.

5. Full coverage PFM crowns with metal wings were cemented over the prepared teeth using the dual cure resin cement (Calibra; Dentsply, York, Pennsylvania, USA) (fig. 10).

Figure 10. A, Labial view of full coverage PFM crowns and resin-bonded bridge combination in patient's mouth. B, Occlusal view of full coverage PFM crowns and resin-bonded bridge combination in patient's mouth.

The patient was overwhelmed with the excellent esthetic and the treatment outcome. The patient was taught about the hygiene maintenance and instructed about the importance of hygiene maintenance and recalled for the regular follow up.

DISCUSSION

The conventional 3-unit bridge offers good retention and esthetic and disadvantage includes the need for tooth reduction which may lead to loss of vitality of the tooth.[3] The advantage of resin-bonded bridge is the conservation of tooth structure and cheaper compared to conventional bridge and disadvantage is its debonding from the tooth.[4] Initially, resin-bonded bridge failed through frequent debonding, but advancements in technology (treatment of the fitting surface and bonding techniques) have improved their predictability. Originally these bridges were retained purely through adhesion, but now minimal preparation of the abutment teeth may be done to enhance mechanical resistance and retention forms. This enables delivery of a more predicable long-term restoration.[5] The 5-year survival rates of both conventional bridge and resin-bonded bridge are high; 87.7% for the resin-bonded bridge whereas 90% for the conventional bridge is over.[3,6]

In this case, a combination of full coverage crowns and resin-bonded bridge was used and it has following advantages of both full coverage crowns and resin-bonded bridged; economical and less invasive, food retention, provides excellent esthetic results as well as comfort, less chance of debonding. This combination can be also indicated in maxillary anterior region in cases of missing #11 and #12. The disadvantage is this combination has rigid connectors. But, as the force on anterior teeth is less compared to posterior teeth, hence this combination can be used in anterior teeth without use of non-rigid connectors.[7] The main limitation of this combination is complexity in fabrication.

The full coverage PFM crowns and resin-bonded bridged combination is a good option for the fixed treatment with missing two centrals mandibular or maxillary arch. It is an economical and less invasive and provides excellent esthetic results as well as comfort to the patient.

REFERENCES

1. Bruno SA. A one-piece fixed bridge. *J Prosthet Dent.* 1995;5(3):401-7.
2. Whiteside WD. A practical mandibular anterior pontic. *J Prosthet Dent.* 1959;9(1):119-20.
3. Pjetursson BE, Bragger U, Lang NP, Zwahlen M, Comparison of survival and complication rates of tooth-supported fixed dental prostheses (FDPs) and implant-supported FDPs and single crowns (SCs). *Clin Oral Implants Res.* 2007;18:97-113.
4. Durey KA, Nixon PJ, Robinson S, Chan MFWY. Resin bonded bridges: techniques for success. *Br Dent J.* 2011;211:113-8.
5. Lally U. Resin-bonded fixed partial dentures past and present – an Overview. *J Ir Dent Assoc.* 2012;58(6):294-300.
6. Pjetursson BE, Tan WC, Tan K, Bragger U, Zwahlen M, Lang NP. A systematic review of the survival and complication rates of resin-bonded bridges after an observation period of at least 5 years. *Clin Oral Implants Res.* 2008;19:131-41.
7. Kumar P, Singh V, Goel R, Singh HP. Non-rigid connector in fixed partial dentures with pier abutment: An enigma simplified. *Int J Health Allied Sci.* 2012;1:190-3.