

Comparison of Two Entry Methods for Laparoscopic Port Entry

Yadav RP, Paudyal N, Bhattarai A, Adhikari D

Department of General Surgery
Nobel Medical College and Teaching Hospital
Kanchanbari-04, Biratnagar, Nepal.

Corresponding Author

Rohit Prasad Yadav
Department of General Surgery
Nobel Medical College and Teaching Hospital
Kanchanbari-04, Biratnagar, Nepal.
E-mail: yadavrohit3057@gmail.com

Citation

Yadav RP, Paudyal N, Bhattarai A, Adhikari D. Comparison of Two Entry Methods for Laparoscopic Port Entry. *Kathmandu Univ Med J.* 2021;74(2):186-9.

ABSTRACT

Background

The first step in laparoscopic surgery is to establish the pneumoperitoneum for which many approaches have been introduced to minimize the complications. Although controversies exist regarding the most efficient technique, till now the best entry technique is still unsettled.

Objective

To compare the safety, operating time and outcome of Direct Trocar Insertion with a well-established and widely practised Open Access Technique.

Method

This is a prospective study at Nobel Medical College Teaching Hospital from November 2019 to February 2021. Patients were grouped into either of the two groups, Group 1 for Direct Trocar Insertion and Group 2 for Open Access Technique. They were later analysed for major and minor complications of the technique and a comparison of either method was done at the end of the study period.

Result

A total of 823 patients were enrolled in the study. Among the study population, 411 patients had Direct Trocar Insertion while 412 patients had Open Access Technique. The majority of the operation that was done during the study period was laparoscopic cholecystectomy. Patients in the Open Access Technique group experienced more complications compared to Direct Trocar Insertion group.

Conclusion

Despite the fear of adopting the Direct Trocar Insertion, this is a safe, better and quick technique for laparoscopic port entry. However, any surgeon practising laparoscopic surgery should be competent to adopt either technique to overcome failure in either process during port entry.

KEY WORDS

Cholecystectomy, Laparoscopic surgery, Pneumoperitoneum

INTRODUCTION

Laparoscopy (Gr: Laparo-abdomen, scopein-to examine) is the art of examining the abdominal cavity and its contents.¹ The first step in laparoscopic surgery is to establish the pneumoperitoneum.² Particularly, insertion of surgical instruments through small incisions to achieve the pneumoperitoneum is the one challenge of laparoscopy. Abdominal access is therefore associated with injuries to the gastrointestinal tract and major blood vessels, and at least 50% of these major complications occur before commencement of the intended surgery.¹

As a majority of the injury occur during the insertion of trocar using the umbilicus as the primary port, several techniques, instruments and approaches have been introduced to minimize the injury. Some commonly used techniques include a. Veress needle technique, b. Direct Trocar Insertion (DTI) technique, c. Optical trocar insertion technique and d. Open Access Technique (OAT). The techniques adopted by the laparoscopic surgeon may vary based on the surgeon's experience and the facilities available within a hospital setting.¹ DTI although was been in existence for 40 years, it has not been adopted by practising surgeons. Fear of causing injury to underlying abdominal structures by this blind procedure appears to be the main reason for the limited practice of this procedure.²

The main aim of this study was to compare the complications, operating time and outcome of DTI with well-established and widely practised OAT.

METHODS

This is a prospective study conducted at the department of general and laparoscopic surgery at Nobel Medical College Teaching Hospital (NoMCTH) from November 2019 to February 2021. Participants were grouped into either of the two groups, Group 1 for DTI and Group 2 for OAT. All patients with symptomatic cholelithiasis and appendicitis who were fit for general anaesthesia were the study population. Patients with conditions like pregnancy, emergency surgery for other coexisting comorbidities, prior history of exploratory laparotomy, prior upper abdominal surgery, primary/ secondary peritonitis and respiratory problems were excluded from the study. Permission from the ethical review committee of NoMCTH was taken before starting the study.

The operation technique adopted during the study is as follows.

Technique for DTI:

First, a supraumbilical skin incision was made. Blunt dissection was made through the subcutaneous layer up to the fascia. After the incision, the anterior abdominal wall was held by the nondominant (left) hand with a dry gauge piece and lifted up. A 10 mm sharp metal safety



Figure 1. Safety trocar with

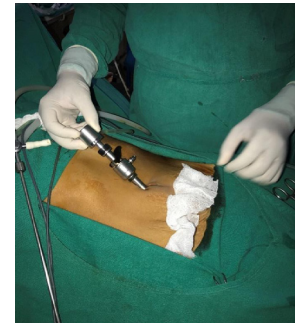

Figure 2. Direct trocar insertion technique

trocar/cannula as shown in figure 1 was held in the dominant (right) hand with the base of the trocar resting at the junction of the thenar and hypothenar eminence, and the index finger used as a guard against sudden and uncontrolled penetration into the peritoneal cavity. Then, with the dominant hand holding the trocar and aiming toward the side of elevation, twisting semicircular motion was continued till a "give"/ click sound of safety trocar was felt. At this time the trocar was withdrawn, and a cannula was further inserted by 2–4 cm depending upon the thickness of the abdominal wall. Then insufflation was started. A gradual increase in intraperitoneal pressure was noted. Entry into the peritoneum was confirmed by putting the scope into the cannula. The procedure is shown in figure 2. After the completion of the procedure, the ports were closed with the number 1 vicryl suture.

Technique for OAT:

Hasson technique was used to achieve the desired result. In this, initially, a supraumbilical incision was made. Blunt dissection was made through the subcutaneous layer up to the fascia. Then retractors were placed in the incision and the fasciae were seen. Then stay sutures were placed on either side of the linea alba with number 1 vicryl suture and were lifted upwards. Then the fascia and the peritoneum were incised in the midline. The peritoneal cavity was entered by the cannula placed over a blunt obturator. After completion of the operation, the port was closed by a previously applied vicryl suture.

The primary endpoint of the study was any major complications occurring due to the port entry method including solid organs, blood vessel and bowel injury.




Figure 3. 10 mm Hassen cannula

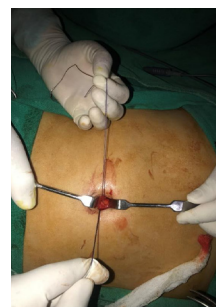

Figure 4. Stay sutures taken in rectus

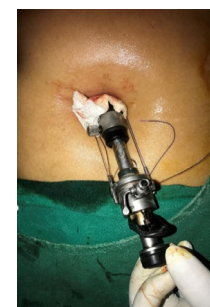

Figure 5. Insertion and fixation of Hassen cannula.

Secondary endpoint included complications like hematoma, subcutaneous emphysema, gas leakage from the umbilical port and time taken for the insertion of the port. Entry time was defined by the time interval between the skin incision and the introduction of the laparoscope into the peritoneal cavity. The cannula is shown in figure 3 and the procedure is shown in figure 4-5.

Patients were assessed intraoperatively, 12 hours after the surgery on the first postoperative day and, at the time of discharge for any complications. Quantitative data are expressed in mean \pm standard deviation and qualitative data are expressed in number and percentage.

RESULTS

A total of 823 study participants were enrolled in the study. Among the study population, 411 patients were had DTI while 412 patients had OAT. Among the total study population, 625 were females and 198 were males. Age ranged from 4 years to 81 years with a mean age of 41.183 ± 16.11 years. The mean age among patients who underwent DTI was 41.31 ± 16.51 years while the mean age of patients who underwent OAT was 41.05 ± 15.74 years.

The majority of the operations that were done during the study period were laparoscopic cholecystectomy (83.8%) followed by laparoscopic appendectomy (16.2%). The complications that occurred out of either operative procedures (OAT or DTI) were minimal. Major complications following the procedure included gas leak (4.9%) followed by hematoma (1.2%). However, the complications were found to be occurring more with OAT (6%) compared to DTI (0.2%). Complications that occurred with either procedure are shown in more detail in table 1 and the operations in which the complications occurred are shown in table 2.

Table 1. Complications encountered during port creation.

Complications	Technique used	
	DTI (Number)	OAT (Number)
Bowel injury	0	0
Bladder injury	0	0
Vascular injury	0	0
Emphysema	0	0
Gas leak	1	39
Hematoma formation	1	9
Failure	8	0

Table 2. Complications encountered during individual operations.

Complications	Laparoscopic cholecystectomy	Laparoscopic appendectomy
Gas leak	32	8
Emphysema	0	0
Hematoma	10	0
Failure	8	0

With regards to the incision length, there was not much difference among either procedure. The mean skin incision required for insertion of the trocar in DTI was 13.35 mm and in OAT was 14.05 mm. Time taken to enter into the peritoneal cavity was almost twice in OAT (147 seconds) compared to that of DTI (76 seconds). On the mean visual analogue scale, patients experienced more pain with OAT (VAS: 3.28 ± 1.33) compared to that of the DTI (VAS: 3.22 ± 1.304). During the study, failure occurred only with DTI insertion which required conversion into the open method (1.94% vs 0%).

DISCUSSION

Modern-day surgery has experienced rapid advances in the field of laparoscopic surgery.¹ Although controversies exist regarding the most efficient technique for creating pneumoperitoneum during laparoscopic surgery, only a handful of articles succinctly describe the best entry technique. Bowel injuries and vascular injuries remain the major complications of these techniques.² Many of these injuries are also underreported, which may be the cause of unclear distinction regarding the superiority of the techniques used.

Direct trocar insertion technique:

Dingfelder was the first to publish (in 1978) on the direct entry into the peritoneum with the help of a trocar.³ The advantage of this technique is the avoidance of complications related to other techniques like failed pneumoperitoneum, intestinal insufflation, CO₂ embolism.⁴ In a study done by Jacobson et al. involving 1223 patients, no single patient had major complications.⁵ Similar studies done by Falahatkar et al. and Angioli et al. showed that the DTI is a more superior method compared to OAT.^{6,7} In one meta-analysis by Molloy et al. DTI had less bowel injury compared to OAT.⁸ Our study also showed no major complications in group 1. Minor complications like a gas leak and hematoma formation in the DTI technique were less compared to those in the OAT group. Meticulous insertion of the trocar and cannula by an experienced surgeon in laparoscopic surgery for the last 15 years, may be the reason why no major events occurred during our study period. However, we believe, every surgeon doing laparoscopic surgery should be competent in both methods of port entry as if DTI fails, a surgeon has to adopt another method.

DIT also has the advantage of having the least entry time compared to OAT. In a study done by Kaistha et al, the mean entry time was 80 seconds. The mean entry time in our study (76 seconds) is almost similar to that of Kaistha et al.⁹ Least entry time is useful in decreasing the total duration of operation, reducing the burden of general anaesthesia and reducing the metabolic stress due to surgery.

Open access technique:

Hasson first described the technique in 1971.³ As this technique is mostly adopted in the learning and beginning phase of the laparoscopic procedure, young surgeons often use this technique to develop their laparoscopic skills.¹⁰ However, the OAT has more reported complications compared to DTI.⁴ As per the meta-analysis conducted by Molloy et al. bowel injury had an incidence of 1.1/1000.⁸ Results of Jacobson et al. also show similar findings.⁵ We did not encounter major complications, however, minor complications of gas leakage, and the hematoma was significantly high during our study.

As open procedures are used commonly for high-risk patient i.e., those with previous abdominal surgery or in obesity, the rate of complications might have been higher. Investigations show that up to 50% of subjects with a midline incision and 20% with a low transverse incision will have some degree of periumbilical adhesions.³ An additional factor for the higher incidence of complications with the OAT may be the surgical learning curve that young laparoscopic surgeons have to overcome.^{4,10} OAT also doesn't necessarily allow good visualization at the point of entry especially in obese patients. Compensation for

this is sometimes made by making larger incisions, thus neglecting the pain reduction advantages of laparoscopy.⁴ In our study, no young surgeons were involved in doing the technique and the hematoma was due to the need to extend the incision beyond the primary incision to allow good visualization.

Because of the limited study population within one tertiary hospital setting, the results of the study may not be generalizable to everyone. A multi-central study with a higher sample size may be required for more accuracy.

CONCLUSION

With limited studies in the literature regarding the comparison between DTI and OAT, we believe this study also further strengthens on DTI being a safe, quick and better technique for laparoscopic access compared to OAT. Despite the underutilization and existing fear in adopting this technique, DTI is more suitable for surgeons wanting fewer operative complications and lesser operative time. We also believe a surgeon should be competent to adopt either technique to overcome failure in either process during port entry.

REFERENCES

- Vilos GA, Ternamian A, Dempster J, Laberge PY. No. 193-Laparoscopic Entry: A Review of Techniques, Technologies, and Complications. *J Obstet Gynaecol Can.* 2017;39(7):e69-e84.
- Laparoscopic Access: Direct Trocar Insertion Versus Open Technique. *Journal of Laparoendoscopic and Advanced Surgical Techniques.* 2019;29(4):489-94.
- Siddaiah-Subramanya M, Tiang KW, Nyandowe M. A New Era of Minimally Invasive Surgery: Progress and Development of Major Technical Innovations in General Surgery Over the Last Decade. *Surg J (N Y).* 2017;3(4):e163-e6.
- Ahmad G, Gent D, Henderson D, O'Flynn H, Phillips K, Watson A. Laparoscopic entry techniques. *Cochrane Database Syst Rev.* 2015;8:Cd006583.
- Jacobson MT, Osias J, Bizhang R, Tsang M, Lata S, Helmy M, et al. The direct trocar technique: an alternative approach to abdominal entry for laparoscopy. *JSLs.* 2002;6(2):169-74.
- Falahatkar S, Nadjafi-Semnani M, Panahandeh Z, Allahkhah A, Emadi S, Motevali S, et al. Direct Trocar Insertion Compared With Open Laparoscopy (Hasson Technique) in Patients Undergoing Urolaparoscopic Surgery. *Urotoday International Journal.* 2009;02.
- Angioli R, Terranova C, De Cicco Nardone C, Cafà EV, Damiani P, Portuesi R, et al. A comparison of three different entry techniques in gynecological laparoscopic surgery: a randomized prospective trial. *Eur J Obstet Gynecol Reprod Biol.* 2013;171(2):339-42.
- Molloy D, Kaloo PD, Cooper M, Nguyen TV. Laparoscopic entry: a literature review and analysis of techniques and complications of primary port entry. *Aust N Z J Obstet Gynaecol.* 2002;42(3):246-54.
- Kaistha S, Kumar A, Gangavatiker R, Br S, Sisodiya N. Laparoscopic Access: Direct Trocar Insertion Versus Open Technique. *Journal of Laparoendoscopic and Advanced Surgical Techniques.* 2019;29.
- Taye MK, Fazal SA, Pegu D, Saikia D. Open Versus Closed Laparoscopy: Yet an Unresolved Controversy. *J Clin Diagn Res.* 2016;10(2):Qc04-7.