

Laparoscopic Cholecystectomy and Common Bile Duct Exploration in Situs Inversus Patients

Simkhada S, Malla B, Shrestha R

Department of Surgery,
Dhulikhel Hospital, Kathmandu University Hospital,
Kathmandu University School of Medical Sciences,
Dhulikhel, Kavre, Nepal.

Corresponding Author

Suyog Simkhada
Department of Surgery,
Dhulikhel Hospital, Kathmandu University Hospital,
Kathmandu University School of Medical Sciences,
Dhulikhel, Kavre, Nepal.
E-mail: suyog.simkhada@yahoo.com

Citation

Simkhada S, Malla B, Shrestha R. Laparoscopic Cholecystectomy and Common Bile Duct Exploration in Situs Inversus Patients. *Kathmandu Univ Med J.* 2021;74(2):271-4.

ABSTRACT

Situs inversus is a congenital condition in which the major visceral organs are reversed from their normal positions, estimated to occur in 1 in 5000–20,000 births. Incidence of gallbladder stone disease is same in these patients and normal patients. Laparoscopic cholecystectomy remains the treatment modality, and performing it successfully in these patients even rarer. We report a 54 years gentleman with gall stone, and 63 years lady who had both gall stone and common bile duct stone along with situs inversus. The mirror image reversibility of the abdominal viscera was seen in both cases. Ports were placed on the opposite side as the liver and the gallbladder were on the left side. Dissection was difficult because being a right-handed surgeon, the non-dominant hand would be the working hand. However, no perioperative complications occurred. It is technically challenging and requires a proper orientation of the left upper quadrant of abdomen.

KEY WORDS

Common bile duct exploration, Laparoscopic cholecystectomy, Situs inversus

INTRODUCTION

Situs inversus is a rare (prevalence being 0.04% to 0.30%) autosomal recessive condition.¹ Situs inversus is of two types: situs inversus partialis, which involves thoracic organs (dextrocardia) or abdominal viscera, and situs inversus totalis (SIT), which involves thoraco-abdominal viscera.² Incidence of gallbladder (GB) stone disease is same in these patients and normal patients. Disease of the biliary tract including common bile duct (CBD) stones can also occur in patients with SIT. However, surgical procedure is more difficult due to the “mirror-image” anatomy.³ Situs inversus does not predispose one to gallstone disease, but it leads to diagnostic confusion.⁴ Laparoscopic cholecystectomy is technically challenging and requires proper orientation of the left upper quadrant. Still it is widely accepted as the treatment of choice for symptomatic cholelithiasis, along with CBD exploration.⁵ Various literature reviews have described reports of laparoscopic management using different techniques in patients with situs inversus with symptomatic gallstones.^{6,7}

CASE REPORT

A 54 years gentle man, a known case of type two diabetes, presented with dull aching upper abdominal pain for 5 months, which was more over the right hypochondrium than the left hypochondrium, which was associated with occasional nausea and aggravated by the intake of fatty and spicy foods. There was no alcohol intake or smoking, no history of weight loss, fever, yellowish discoloration of eyes or body or vomiting. Bladder and bowel habits were normal. His general condition was fair, and he was of an average built. On abdominal examination, there was tenderness over both right and left hypochondrium, on deep palpation. However, Murphy’s sign was absent. There was no mass palpable. Liver function test (LFT) was normal. Further investigations in terms of chest x-ray, ultrasonography (USG) of abdomen as well as Magnetic Resonance Cholangiopancreatography (MRCP) confirmed situs inversus totalis with cholecystolithiasis (1.5x1 cm).

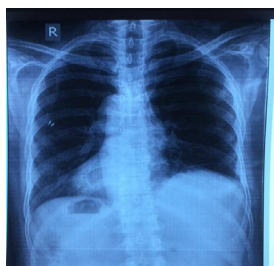


Figure 1. Chest X-ray with dextrocardia

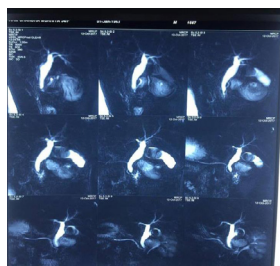


Figure 2. MRCP showing gallbladder with stones

After proper positioning of the patient, a 10 mm port was placed in the sub-umbilical region (the camera port), followed by another 10 mm port, placed left to the epigastric region, approximately 3 cm away. Two 5 mm ports were placed along the left mid-clavicular and left anterior axillary line. The epigastric port and the port along the left anterior axillary line were the main working ports. The surgical techniques were modified in a mirror image fashion in order to provide access to the left upper quadrant i.e. it required the surgeon and the assistant to stand on right side, with the monitor placed on the left side. After entering into the abdomen, SIT with liver and gallbladder in the left hypochondrium and spleen in the right hypochondrium was confirmed.

Assistant grasped the fundus of the gallbladder and pulled it up wards and laterally via the left lateral port. We grasped Hartmann's pouch and pulled it laterally using left hand via the epigastric port, and dissected the adhesion using right hand via the left midclavicular port. Identification of Calot's triangle was difficult because the anatomy could not be clearly identified as a result of the previous inflammation. Difficulty was also encountered in skeletonizing the structures in Calot's triangle. Once the cystic duct and artery had been individually clipped and divided safely, the gallbladder was separated from its bed by electrocautery, as usual and extracted in a retrieval bag through the camera port, under direct vision. The operation was successfully completed in 60 minutes. Finally, a 20 French (Fr) drain was kept in the gallbladder bed from left hand side. There were no intraoperative complication. The gallbladder specimen was sent for histopathological examination (HPE). The drain was removed and the patient was discharged on the fourth postoperative day without any postoperative complications.

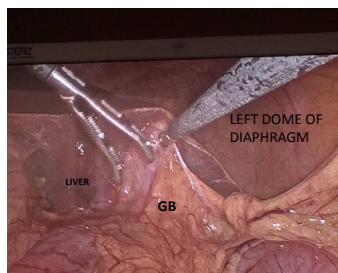


Figure 3. Intraoperative anatomy

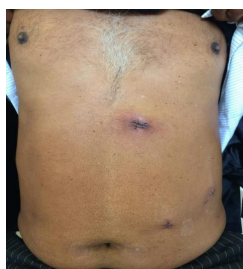

Figure 4. On 4th postopday

A 63 years lady from Dharan, a known case of hypertension, hypothyroidism and CKD under medication, presented with epigastric pain for four months, aggravated by spicy food, on and off type. There was no history of fever, vomiting, yellowish discoloration of eyes or body. Physical examination including systemic examination was grossly normal, except the heart sounds were heard over the right precordium, signifying dextrocardia. All the preoperative investigations including LFT yielded normal findings. ERCP was done with the opposite maneuver, and due to technical difficulty, the ampulla could not be identified and cannulation could not be done. MRCP showed SIT with choledocholithiasis (9.8x7.2 mm) with mildly dilated CBD and Intra-hepatic biliary radicles (IHBR), with multiple small stones in the gallbladder.

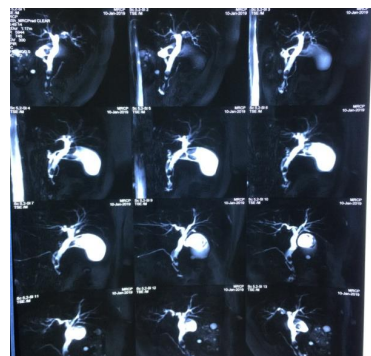


Figure 5. MRCP showing multiple GB calculi with stone in common bile duct (CBD)

The patient was kept in lithotomy position, so that the surgeon could stand in middle and the monitor kept over left side of the patient. In this case, we needed to modify our technique in a mirror image fashion to gain access to the left upper quadrant. The position of the surgeon and the ports were introduced in a mirror image of the conventional setup. Secondly, attention was paid to exchanging the roles of both hands, which were mainly dissection with left hand and traction with right. The technical refinement of left hand was particularly helpful. The first 10 mm trocar was inserted into the umbilical port after pneumoperitoneum had been established, and was used as a route for the telescope. SIT was confirmed using a telescope via an umbilical incision. The liver and the gallbladder were located on the left side, whereas the spleen and the stomach were located on the right. The second and third 10 mm trocars were inserted in the midline at the subxiphoid area and in the midclavicular line below the left costal margin, respectively, and were used as the working ports. The third port, in the midclavicular line was also used as a route for the choledochoscope. A fourth 5 mm port was inserted in the anterior axillary line above the anterior superior iliac spine. The anterior wall of the CBD was carefully cleared. A small longitudinal choledochotomy was made using scissors and stones were extracted using endo-forceps. Then a flexible choledochoscope (5 mm, 4 DOF, CHF-P20Q, Olympus) was then inserted into the duct and advanced both proximally and distally, to observe the distribution of the stones along with the ductal structure,

as well as to confirm the presence of residual stones. Intraoperative and postoperative period was uneventful. Patient discharged on the 5th postoperative day.

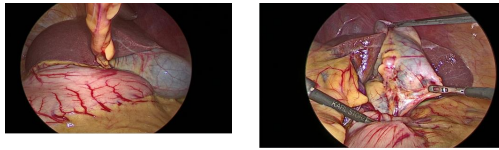


Figure 6. Cholecystectomy being done

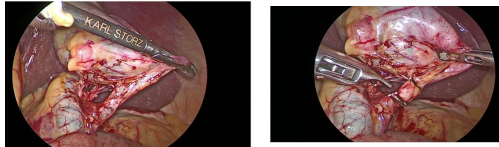


Figure 7. Stone retrieval

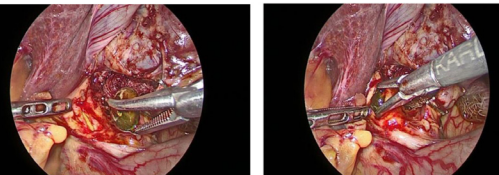


Figure 8. Choledoscopy to look for the patency and any residual stone

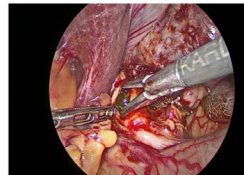


Figure 9. CBD sutured

DISCUSSION

Situs inversus is a congenital condition in which the major visceral organs are reversed or mirrored from their normal positions which is estimated to occur in 1 in 5000–20,000 birth.² Though situs inversus on its own is not pathological, it may be associated with cardio-respiratory, Hepato-pancreato-biliary, gastrointestinal, neurological, orthopedic and urological anomalies, some of which may be life-threatening.⁸ The ergonomics of a right-handed surgeon standing on the right side of the patient demand that either he crosses hands so as to allow the right hand to operate through the epigastric port or use the assistant to retract the Hartmann's pouch from the left side or as we have described here, use the epigastric port to retract with the left hand and operate with the right hand through the lateral subcostal port.⁴ In our case, we did cholecystectomy

and CBD exploration in mirror image view, using left hand use as predominant hand.

Laparoscopic cholecystectomy as well as CBD exploration in these patients is technically challenging and requires proper orientation of the left upper quadrant. Still it is widely accepted as the treatment of choice for symptomatic cholelithiasis as well as CBD stones.⁵

The anatomical variation and, mainly, the contralateral disposition of the biliary tree demand an accurate dissection and exposure of the biliary structures to avoid iatrogenic injuries.

Skeletonizing the gall bladder and dissecting the Calot's had to be done meticulously and precisely, getting oriented to the opposite anatomy. The skeletonizing of the structure of Calot's triangle consumes extra time and is more difficult than in patient with a normally located gallbladder. Some have overcome such difficulties by standing between two abducted lower limbs like we did in our second case, in case of laparoscopic CBD exploration.^{9,10} However for laparoscopic cholecystectomy, we had to stand on the right side of patient. Apart from mirror image transposition, patients with situs inversus usually do not have associated extrahepatic biliary, venous and arterial anomalies. Hence, it appears that the surgeon should not be discouraged from performing laparoscopic cholecystectomy for situs inversus on the ground of unexpected associated biliary tract anomalies.¹¹ SIT may make identifying the CBD difficult as well as increasing the risk of iatrogenic injury to many visceral organs, that has to be taken into account before starting the procedure.¹²

Situs inversus totalis is an extremely rare condition and performing successful laparoscopic cholecystectomy in these patients is even rarer. Ergonomics and positioning for a right-handed surgeon are important points for a smooth surgery. Technical difficulties merit consideration, the mirror image reversibility of the abdominal viscera requires the surgeon to stand on opposite side and work with opposite hand. The principle of surgery remains the same as conventional laparoscopic cholecystectomy and CBD exploration. Thus, it can be concluded that a laparoscopic exploration of the CBD and a laparoscopic cholecystectomy can be performed safely in patients with SIT after reorienting the visual-motor skills to the left upper quadrant.

REFERENCES

1. Iskandar ME, Radzio A, Krikhely M, Michael Leitman I. Laparoscopic cholecystectomy for a left-sided gallbladder. *World J Gastroenterol*. 2013;19(35):5925-8.
2. Arya SV, Das A, Singh S, Kalwaniya DS, Sharma A, Thukral BB. Technical difficulties and its remedies in laparoscopic cholecystectomy in situs inversus totalis: A rare case report. *Int J Surg Case Rep*. 2013;4(8):727-30.
3. Polychronidis A, Karayiannakis A, Botaitis S, Perente S, Simopoulos C. Laparoscopic cholecystectomy in a patient with situs inversus totalis and previous abdominal surgery. *Surgical Endoscopy*. 2002;16:1110.
4. Salama IA, Abdullah MH, Houseni M. Laparoscopic cholecystectomy in situs inversus totalis: Feasibility and review of literature. *Int J Surg Case Rep*. 2013;4(8):711-5.
5. Sato M, Watanabe Y, Iseki S, Akehi S, Tachibana M, Sato N, et al. Hepatolithiasis with situs inversus: First case report. *Surgery*. 1996;119(5):598-600.
6. Eisenberg D. Cholecystectomy in situs inversus totalis: a laparoscopic approach. *Int Med Case Rep J*. 2009;27.

7. Patle NM, Tantia O, Sasmal PK, Khanna S, Sen B. Laparoscopic Cholecystectomy In Situs Inversus-Our Experience of 6 Cases. *Indian J Surg.* 2010;72(5):391-4.
8. VARANO NR, MERKLIN RJ. Situs inversus: review of the literature, report of four cases and analysis of the clinical implications. *J Int Coll Surg.* 1960;33:131-48.
9. Yaghan RJ, Gharaibeh KI, Hammori S. Feasibility of Laparoscopic Cholecystectomy in Situs Inversus. *J Laparoendosc Adv Surg Tech.* 2002;11(4):233-7.
10. Watson CJE, Rasmussen A, Jamieson NV, Friends PJ, Johnson PS, Barnes ND, et al. 1995 Watson - Liver tx in SI.pdf. *Br J Surg.* 1995;82:242-5.
11. Chandraraj S. Observations on some additional abnormalities in Situs inversus viscerum. *In: Journal of anatomy.* 1976;377-88.
12. Peters JH, Ellison EC, Innes JT, et al. Safety and efficacy of laparoscopic cholecystectomy: a prospective review of 100 initial patients. *Ann Surg.* 1991;213:3-12.