

# Crown Lengthening Surgery for Enhancing Restorative Treatment in Esthetic Zone

Dawadi A,<sup>1</sup> Humagain M,<sup>1</sup> Sapkota B,<sup>2</sup> Subba M,<sup>1</sup> Neupane M,<sup>1</sup> Lamichhane S<sup>1</sup>

<sup>1</sup>Department of Periodontology and Oral Implantology

<sup>2</sup>Department of Prosthodontics

Kathmandu University School of Medical Sciences

Dhulikhel, Kavre, Nepal.

## Corresponding Author

Asmita Dawadi

Department of Periodontology and Oral Implantology

Kathmandu University School of Medical Sciences

Dhulikhel, Kavre, Nepal.

E-mail: asmitadawadi63@gmail.com

## Citation

Dawadi A, Humagain M, Sapkota B, Subba M, Neupane M, Lamichhane S. Crown Lengthening Surgery for Enhancing Restorative Treatment in Esthetic Zone. *Kathmandu Univ Med J.* 2021;74(2):278-81.

## INTRODUCTION

Crown lengthening is a surgical procedure designed to increase the extent of supragingival tooth structure for restorative or esthetic purposes by apically positioning the gingival margin, removing supporting bone, or both.<sup>1</sup> It is one of the most common surgical procedures in a periodontal practice.<sup>2</sup> According to a survey done by the American Academy of Periodontology in 2003, about 10% of all periodontal surgical procedures are done to obtain clinical crown length.<sup>3</sup>

Infringement of the biologic width and insufficient ferrule are the major problems with short clinical crown, subgingival caries, or extensive caries that shortens the tooth or fracture. Crown lengthening can help a clinician to form a biological width and a ferrule length. The indications for crown-lengthening surgery are an esthetic improvement, disclosure of subgingival caries, disclosure of a fracture, or some combination of those.<sup>4,5</sup>

## ABSTRACT

For obtaining adequate retention for restoring cases like subgingival caries or extensive caries that shortens the tooth, short clinical crown, and fractures, it is usually necessary to disclose more tooth structure. Crown lengthening procedure is done to increase the clinical crown length for restorative or esthetic reasons without breaching the biologic width. These procedures are also utilized to improve the appearance and retention of restorations placed within the esthetic zone. We report a case of crown lengthening surgery with an internal bevel gingivectomy which was done in our department without compromising tooth support and esthetics.

## KEY WORDS

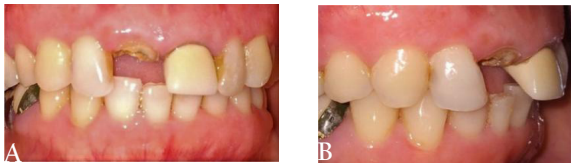*Crown lengthening, Esthetics, Gingivectomy*

Many treatment approaches including gingivectomy, apically positioned flap with or without osseous resection, and forced eruption alone or in combination with surgical crown lengthening are recommended for crown lengthening.<sup>6</sup> The preference of treatment approach depends on many factors like a clinical crown to root ratio, esthetics, root morphology and proximity, location of furcation, individual and assembled tooth position, and restorability of the teeth.<sup>5,6</sup>

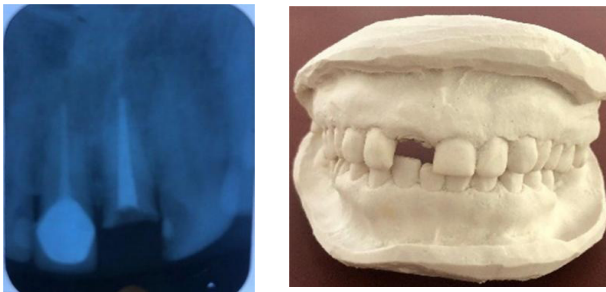## CASE REPORT

A 43 year-old female visited the dental department of Dhulikhel hospital with a chief complaint of the dislodged crown in the upper front teeth region. She had a non-contributory family and medical history. On extra-oral examination, she had a high lip line and gingival display

while smiling. Intra-oral examination showed that her 11 and 21 had been endodontically treated and there was inadequate clinical crown height in relation to 11 for crown placement. On periodontal examination, her oral hygiene status was good with healthy gingiva, no mobility, and sufficient width of keratinized gingiva (fig. 1). The intraoral periapical radiograph showed root canal therapy with respect to #11 and #21 and adequate crown to root ratio for lengthening (fig. 2).



**Figure 1.** Initial clinical photograph of the patient A. front view B. lateral view



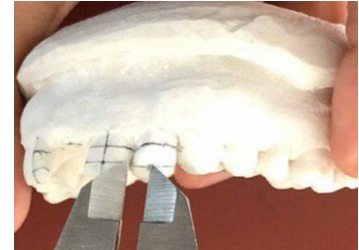
**Figure 2.** Radiograph showing root canal filling **Figure 3.** Cast fabricated

Crown lengthening was recommended after consulting with the restorative dentist to increase the length of the clinical crown. Alginate impressions of the upper and lower arch were made and were immediately poured with plaster of paris for the diagnostic cast (fig. 3). A digital caliper was used for the measurements from maxillary right canine to left canine. We used two reference points [the incisal contact area position (ICAP) and the apical contact area position (ACAP)] to measure the width of the tooth (fig. 4). Center points were marked dividing each width and points were extended apically to define the vertical bisected midline (VBM). The height of the crown was measured along VBM (fig. 5 and 6). The required height of the crown was calculated as the width of the crown is 80 percent of its height. The gingival zenith position (GZP) from the VBM of the clinical crown of central incisors, lateral incisors, and canines were marked at about 1 mm, 0.4 mm distally, and 0 mm, respectively according to a study done by Chu et al. (fig. 7).<sup>7</sup> The gingival zenith level (GZL) for lateral incisors were marked approximately 1 mm coronal to the gingival zenith position of the central incisor and canine teeth (fig. 8).<sup>7</sup>

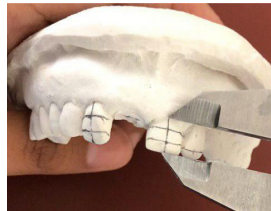
After giving local anesthesia, bone sounding was done around the tooth and we found that more than 3 mm of supracrestal soft tissue was present. The incision level was marked by placing bleeding spots with the tip of the probe as per the planning done in the cast (fig. 9). Using a no.15



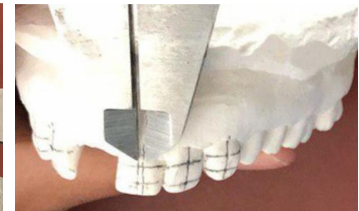
**Figure 4.** The tooth width measured at two reference points using digital caliper.



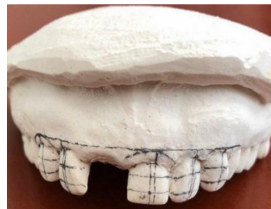**Figure 5.** Width divided in half and centre marked.



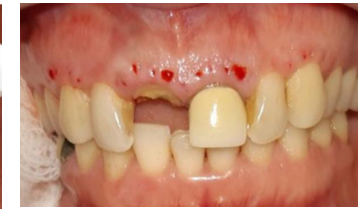**Figure 6.** Center points were extended to define the vertical bisected midline (VBM)



**Figure 7.** The mean location of the GZP from the VBM of the clinical crown marked.

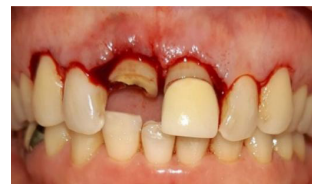

**Figure 8.** Final measurements for placing incision

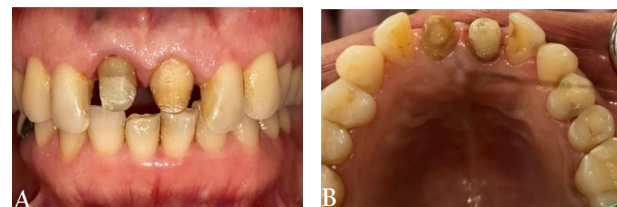

**Figure 9.** The level of incision marked by placing bleeding spots.

Bard-Parker blade, internal beveled gingivectomy was performed along the bleeding points to get ideal contour and zenith on labial and palatal aspect of maxillary right to left canine (fig. 10).

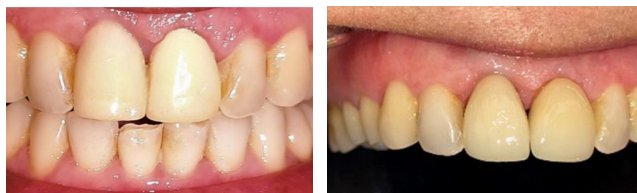

**Figure 10.** Internal bevel gingivectomy performed from maxillary right to left canine



**Figure 11.** Post and core placed A. labial view B. palatal view

Immediately after surgery, a fiber post was placed and resin core build-up was done in relation to #11 and a fitting temporary crown was cemented with respect to #11 and #21 to guide the contour of the gingival tissues during healing (fig. 11A, 11B and 12). Final insertion of the porcelain fused metal crowns in relation to 11 and 21 was done 2 months after the crown lengthening surgery (fig. 13).



**Figure 12.** Insertion of provisional crown with respect to #11 and #21

**Figure 13.** Final insertion of PFM crown with respect to #11 and #21

## DISCUSSION

The establishment of biologic width and preservation of sufficient keratinized gingiva are the two main goals of crown lengthening. Crown margins should not infringe on biological width.<sup>5</sup> Biologic width (BW) is defined as the combined dimension of the epithelial and connective tissue attachments coronal to the crestal bone. Encroachment of the biologic width by placing the margin of restoration within its zone may result in gingival inflammation, pocket formation, and alveolar bone loss.<sup>2,8</sup>

Gargiulo et al. in 1961 reported the average biological width value as 2.04 mm, where the combination of connective tissue attachment (mean value: 1.07 mm) and the epithelial attachment (mean value: 0.97 mm) together form dentogingival junction.<sup>9</sup> Ingber et al. suggested adding 1 mm gingival sulcus depth coronal to the 2 mm biologic width to achieve a minimum extent of 3 mm between the bone crest and a restorative margin needed to allow proper healing and restoration of the tooth.<sup>10</sup> A systematic review conducted by Schmidt et al. in 2013 found similar mean values of biologic width (2.15-2.30 mm), although appreciable intra and inter individual divergence were reported.<sup>11</sup>

If excess keratinized gingiva is present and underlying bone crest is present at 3 mm or more from the gingival incision level, gingivectomy can be done for crown lengthening. Adequate apico-coronal height of keratinized gingival tissues of at least 3 mm should remain post-surgery where there is subgingival restoration. Gingivectomy can be performed using scalpels, electrosurgery, laser, etc. If gingivectomy could lead to less than 3 mm of keratinized postoperative gingiva, then an apically positioned flap without osseous resection should be considered as a treatment approach. In the cases where the osseous level is at less than 3 mm from the level of gingival resection, an apically positioned flap with osseous resection should be used to avoid postsurgical rebound of supracrestal gingival tissue.<sup>4-6</sup> In our case, there was adequate keratinized gingiva and the osseous level was more than 3 mm from the level of gingival resection. Gingivectomy was therefore performed for crown lengthening.

The ferrule is "a metal band or ring used to fit the root or crown of a tooth".<sup>12</sup> The ferrule height of 1-2 mm is needed to be engaged by the crown to allow the forces of occlusion to be distributed onto the periodontal ligament and not

causing stress concentration at the post and core which may increase risk of tooth or restoration failure.<sup>4</sup> There should be a minimum 4 mm length from the most apical level of caries or fracture to the bone crest after crown lengthening to assure margin placement on sound tooth structure and retention form.<sup>7</sup>

Orthodontic extrusion can be a good supplement to crown lengthening when the latter could possibly create a non-harmonious gingival margin in the esthetic area of the mouth and could result in an inadequate crown-root ratio of a tooth.<sup>6</sup> But, as extrusion brings the attachment apparatus of the tooth along with it coronally, additional crown lengthening is also required after the teeth have reached to its intended position.<sup>6</sup> Another disadvantage is that it requires more time, so our patient chose surgical correction over orthodontic extrusion.

In our case, we did crown lengthening using internal bevel gingivectomy. An internal bevel incision can preserve the maximum amount of attached gingiva while thinning down the margin of the gingiva to a knife-edge contour. It is more comfortable for the patient than external bevel gingivectomy (EBG) because of healing by primary intention in the former.<sup>5</sup>

Lip line is very important as it will determine the amount of tooth and gingival display affecting the final esthetic outcome.<sup>13</sup> If only one tooth needs treatment and there is a higher lip line, then the gingival differences will be noticeable and aesthetic outcome will be poor. In our case, the patient had a high lip line, so instead of having a gingivectomy with just one tooth, gingivectomy was performed from canine to canine to get the best aesthetic effects.

Gingival zenith is also an important parameter for enhancing the esthetic effect. A study done by Humagain et al. shows the average GZP of 1.02±0.20 mm for central incisor, 0.51±0.22 for lateral incisor, and 0.15±0.07 for a canine.<sup>14</sup> Generally, the width/height proportions of upper anterior teeth is around 80%.<sup>15</sup> We can apply these points in combination with other esthetic parameters during diagnosis, treatment planning, and in reconstructing a natural smile.<sup>7</sup> We used these parameters in our case to improve the esthetic outcome of the patient.

Proper wound healing should be allowed for esthetic regions of mouth to achieve a good esthetic outcome as there is a continued remodeling of periodontal tissues after crown lengthening surgery. According to the study done by Bragger et al. gingival recession can occur between 6 weeks and 6 months after the surgery.<sup>16</sup> Hence, final crown insertion can be done after the wounds have completely healed which may be up to 6 months. Till then temporary crown should be retained. In this case, final crown insertion was done after 2 months.

In conclusion, crown lengthening surgery is a good option for enhancing restorative therapy or esthetic appearance and provides satisfactory results for both functional as well as esthetic purposes. However, an examination of the overall periodontal condition of the patient should

be evaluated for proper treatment planning for surgery. Also, an accurate diagnostic and interdisciplinary approach are essential for getting enhanced, conservative, and anticipated results in esthetic areas.

## REFERENCES

1. American Academy of Periodontology, editor. In: Glossary of periodontal terms 4<sup>th</sup> ed. Chicago, American Academy of Periodontology; 2001.p11
2. Marzadori M, Stefanini M, Sangiorgi M, Mounssif I, Monaco C, Zucchelli G. Crown lengthening and restorative procedures in the esthetic zone. *Periodontol.* 2000. 2018;77(1):84-92.
3. American Academy of Periodontology. 2003 Practice profile survey: characteristics and trends in private periodontal practice. Chicago, American Academy of Periodontology; 2004.
4. Hempton TJ, Dominici JT. Contemporary crown-lengthening therapy: a review. *J Am Dent Assoc.* 2010;141(6):647-55.
5. Anoop S. Crown lengthening surgery: a periodontal makeup for anterior esthetic restoration. *Journal of Interdisciplinary Dentistry.* 2018;8(3):132.
6. Majzoub ZA, Romanos A, Cordioli G. Crown lengthening procedures: A literature review. *Semin Orthod.* 2014;20(3):188-207.
7. Chu SJ, TAN JH, Stappert CF, Tarnow DP. Gingival zenith positions and levels of the maxillary anterior dentition. *J Esthet Restor Dent.* 2009;21(2):113-20.
8. Melnick PR, Takei H. Periodontal-restorative interrelationships. In: Fermin A. Carranza, editor. Newman and Carranza's Clinical Periodontology 13<sup>th</sup> ed, Philadelphia, Elsevier; 2019.p698e2.
9. Gargiulo AW, Wentz FM, Orban B. Dimensions and relations of the dentogingival junction in humans. *J Periodontol.* 1961;32(3):261-7.
10. Ingber JS. The "biologic width", a concept in periodontics and restorative dentistry. *Alpha Omegan.* 1977;70:62-5.
11. Schmidt JC, Sahrman P, Weiger R, Schmidlin PR, Walter C. Biologic width dimensions--a systematic review. *J Clin Periodontol.* 2013;40(5):493-504.
12. Dent JP. The glossary of prosthodontic terms. *J Prosthet Dent.* 2005;94(1):10-92.
13. Tjan AH, Miller GD, The JG. Some esthetic factors in a smile. *J Prosthet Dent.* 1984;51(1):24-8.
14. Humagain M, Rokaya D, Srii R, Dixit S, Kafle D. Gender based comparison of gingival zenith esthetics. *Kathmandu Univ Med J.* 2016;54(2):148-52.
15. Borges AC, Seixas MR, Machado AW. Influence of different width/height ratio of maxillary anterior teeth in the attractiveness of gingival smiles. *Dental Press J Orthod.* 2012;17(5):115-22.
16. Brägger U, Lauchenauer D, Lang NP. Surgical lengthening of the clinical crown. *J Clin Periodontol.* 1992;19(1):58-63.