

Epidermoid Cyst of the Ear Lobule in Adult

Karmacharya S,¹ Sah SK,¹ Adhikari S²

¹Department of Otorhinolaryngology and Head and neck surgery

²Department of Radiodiagnosis

Janaki Medical College Teaching Hospital,

Ramdaiya, Janakpur, Nepal.

Corresponding Author

Sameer Karmacharya

Department of Otorhinolaryngology and Head and neck surgery

Janaki Medical College Teaching Hospital,

Ramdaiya, Janakpur, Nepal.

E-mail: karmacharyasameer1234@gmail.com

Citation

Karmacharya S, Sah SK, Adhikari S. Epidermoid Cyst of the Ear Lobule in Adult. *Kathmandu Univ Med J.* 2021;76(4):531-3.

INTRODUCTION

Dermoid cysts are often present at birth. They are asymptomatic affecting mainly males.¹ The epidermoid cyst is a common benign disease of the skin caused by inflammation of hair cortex follicles and proliferation of epidermal cells within the dermis or superficial subcutaneous tissue.² It usually arises on hair-bearing areas including the scalp, face, neck, trunk, extremities, and scrotum.³ The condition can be congenital or acquired.⁴⁻⁶ Abscess formation, hemorrhage, and malignant transformation have been reported as complications of epidermoid cysts.⁷ Histopathologic examination of the lesion shows a lining consisting of keratinized, stratified, squamous epithelial cells with the inner surface lined with keratin lamellae.⁸ Complete excision of the cyst contents and cyst wall is the treatment of choice.⁹ We here report a case of a rare entity in clinical practice.

ABSTRACT

An epidermoid cyst is one of the most common benign cysts of the skin. The cyst is filled with keratin flakes and its wall is composed of keratinized, stratified, squamous epithelium. Epidermoid cysts can occur anywhere on the body, usually along the lines of embryonic fusion and mostly on the face, scalp, neck, chest, and upper back. Around 80% of the epidermoid cysts are seen in ovaries and testicles whereas, in the head and neck, they account for only about 7% and 1.6% of epidermoid cysts are reported in the oral cavity. The condition can be congenital or acquired. Congenital causes are rare and may be caused by the entrapment of ectodermal elements intradermally or subcutaneously during embryogenesis. Acquired causes of an epidermoid cyst may result from traumatic or iatrogenic implantation of epithelial cells into the dermal layer or from obstruction of a pilosebaceous unit in the hair follicle. Surgical excision completes the treatment.

KEY WORDS

Auricle, Epidermoid cyst, Keratin

CASE REPORT

A 22 years old male presented to Janaki Medical College ENT OPD with a history of noticing a swelling on the left ear lobule for 11 months. Onset was insidious and gradually progressive. Initially, it was the size of a peanut and over the last 2 months has increased to its present size as that of a small lime (Fig. 1). It was painless. There was no history of noticing another swelling on other parts of the body. On examination, there was a 2x2 cm² swelling on the lobule of the left pinna. It was soft, mobile, and non-tender on palpation. It had a smooth and regular surface without a central punctum. The skin overlying the swelling was normal. There was no ear lobe piercing noted. The rest of the pinna, external auditory canal, and tympanic membrane on the left side were within normal limits. Neck examination revealed no cervical lymphadenopathy. A provisional diagnosis of dermoid/ epidermoid or sebaceous cyst was made (Fig. 1). Doppler ultrasound

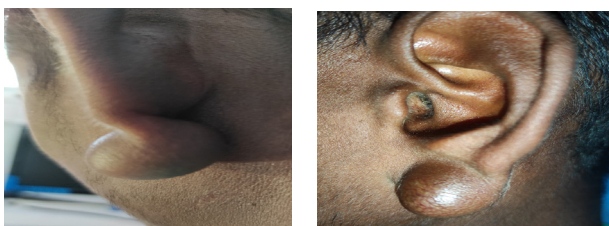

Figure 1. Clinical photograph showing the epidermoid cyst on the left pinna lobule.

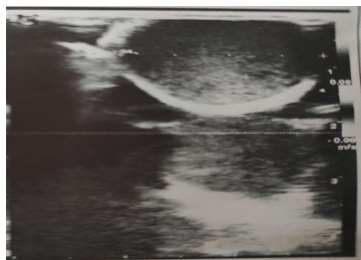


Figure 2. There was a well-defined, oval, hypoechoic cystic lesion in left ear lobule, subcutaneous tissue plane with low level internal echoes and posterior acoustic enhancement. The lesion was thin walled without internal color doppler flow. No communicating tracts seen. Perilesional tissue was normal. Features were suggestive of epidermoid cyst.

showed a well-defined, oval, hypoechoic cystic lesion in the left ear lobule, subcutaneous tissue plane with low-level internal echoes, and posterior acoustic enhancement. The lesion was thin-walled without internal color Doppler flow. No communicating tracts seen. Perilesional tissue was normal. Features were suggestive of the epidermoid cyst (Fig. 2). The lesion was excised in total (Fig. 3). The macroscopic finding consisted of soft, cystic, grayish-black, 2x2 cm² tissue (Fig. 3). On sectioning a whitish cheesy material, probably keratin material was found (Fig. 3). Histopathologic examination showed an encapsulated cyst lined by stratified squamous epithelium along with keratin material in the center, suggestive of an epidermoid cyst (Fig. 4). A confirmatory diagnosis of an Epidermoid cyst was made. The patient recovered very well post-operatively.

DISCUSSION

The occurrence of an epidermoid cyst of the auricle is a rare entity. Only a few ear lobe epidermal cysts have been reported in the literature. Epidermoid cysts are also called epithelial dermal inclusion cysts, Infundibular cysts, keratin cysts. In 1859 Roser was the first who described epidermoid cyst.¹⁰ In the head and neck region, the most common location is the lateral eyebrow. Out of all the dermoid cysts, which occur in the head and neck region, 11.5% are noted in the submental region.¹¹ There are two theories for epidermoid cyst formation: Firstly, during early intrauterine life the epidermoid cyst may occur when two epidermal surfaces fuse and an ectodermal implant is retained deep to the surface. Secondly, due to traumatic entrapment of surface epithelium in the connective tissue and further these cells may differentiate to form a cyst.¹² Epidermoid cyst in different locations causes

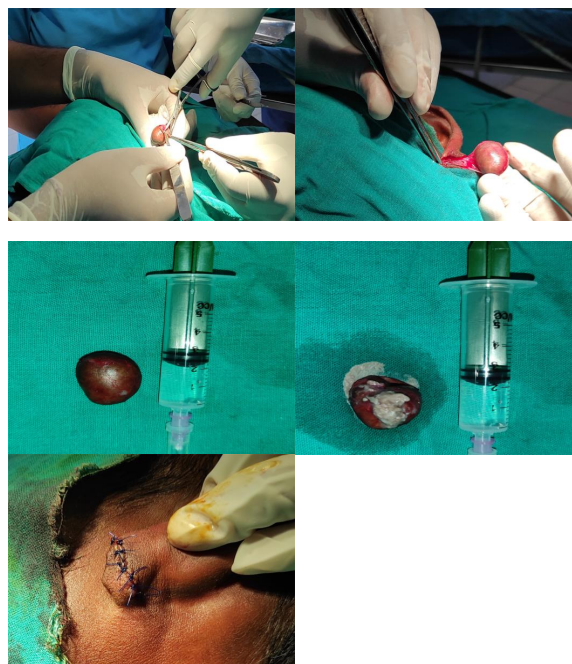

Figure 3. Intra operative photographs of the excision of the left pinna lobule cyst under local anesthesia.

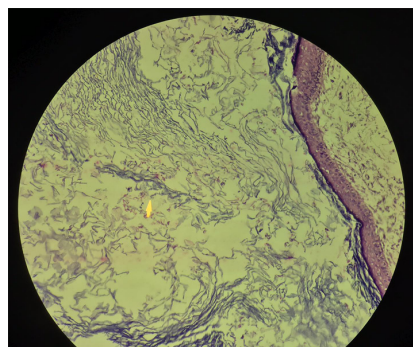


Figure 4. Photomicrograph showing an encapsulated cyst lined by stratified squamous epithelium along with keratin material in the center, suggestive of an epidermoid cyst.

dysphonia, dysphagia, dysarthria, dyspnea, double chin, interference in tongue movement and mastication, speech, and increases in size with time. Unusual manifestations include headache, obstructive sialadenitis, and facial asymmetry have also been reported.¹³⁻¹⁵ Epidermal cysts of the postauricular region must be differentiated from lipomas and hemangiomas. Lipomas are benign fatty tissue containing tumors and hemangiomas which are usually present at birth are benign tumors of the vascular endothelia. FNAC of epidermoid cyst usually shows debris with mature squamous cells with anucleate squames. Inflammatory cells and foreign body giant cells may also be found. The cytological differential diagnosis of epidermoid cyst includes trichilemmal cyst and dermoid cyst.¹⁶ One of the associated problems with large epidermal cysts is their ugly, unaesthetic appearance, so many patients go under the knife for cosmetic reasons, as more often than not epidermal cysts are asymptomatic. An epidermoid cyst should be differentiated from neurofibroma, eruptive vellus hair cyst, pilomatixoma, dermatofibroma, sarcoma, lipoma, and trichilemmal cyst. In an older age group, the

differential diagnoses would include basal cell carcinoma, squamous cell carcinoma, and Bowen disease.¹⁷ If removal of an epidermoid cyst is desired for cosmetic purposes or because of complications, complete excision of the cyst contents and cyst wall is the treatment of choice. Incomplete excision may lead to chronic inflammation

and recurrence.^{6,9} Malignant transformation is an unusual complication that may occur in patients with long-standing dermoid cysts. Carcinomatous transformation to a squamous cell carcinoma is described in sublingual and intra-abdominal dermoid cysts, most often dermoid cysts of the ovary.¹⁸

REFERENCES

1. De Souza BA, Dey C, Carver N. A rare case of the dermoid cyst behind the ear. *Plast Reconstr Surg.* 2003;112:1972.
2. Kim HK, Kim SM, Lee SH, Racadio JM, Shin MJ. Subcutaneous epidermal inclusion cysts: ultrasound (US) and MR imaging findings. *Skeletal Radiol.* 2011;40:1415-9.
3. Jung KH, Choi HJ, Nam DH. Characteristics of dermoid cyst of the auricle. *Arch Craniofac Surg.* 2014;15:22-7.
4. Pereira-Santos D, De Melo WM, Brêda MA Jr, Sonoda CK, Hochuli-Vieira E. Epidermal cyst causing facial asymmetry. *J Craniofac Surg.* 2013;24(2):e112-e114.
5. Pérez-Guisado J, Scilletta A, Cabrera-Sánchez E, Rioja LF, Perrotta R. Giant earlobe epidermoid cyst. *J Cutan Aesthet Surg.* 2012;5(1):38-9.
6. Abdel-Aziz M. Epidermoid cyst of the external auditory canal in children: diagnosis and management. *J Craniofac Surg.* 2011;22(4):1398-1400.
7. Lee DH. Intradiploic epidermoid cyst of the temporal bone: is it the same as or different from cholesteatoma? *J Craniofac Surg.* 2011;22:1973-5.
8. Kang SG, Kim CH, Cho HK, Park MY, Lee YJ, Cho MK. Two cases of giant epidermal cyst occurring in the neck. *Ann Dermatol.* 2011;23(suppl 1):S135-S138.
9. Baek SO, Kim SW, Jung SN, Sohn WI, Kwon H. Giant epidermal inclusion facial cyst. *J Craniofac Surg.* 2011;22(3):1149-51.
10. Brown CA, Barker RD. Dermoid cyst: Report of a case. *J Oral Surg.* 1972;30:55.
11. Suzuki T, Taki M, Shibata T, Matsunami T, Sakaguchi H, Yamamoto S, et al. Epidermal cyst of the bony external auditory canal. *Otolaryngol Head Neck Surg.* 2007;136:155-6.
12. Koca H, Seckin T, Sipahi A, Kaznac A. Epidermoid cyst in the floor of the mouth: report of a case. *Quintessence Int.* 2007;38:473-7.
13. Noffke CE. Implantation-type epidermoid cyst of the mandible. *Dentomaxillofac Radiol.* 1999;28:383-5.
14. Janarthanam J, Mahadevan S. Epidermoid cyst of the submandibular region. *J Oral Maxillofac Pathol.* 2012;16:435-7.
15. Ozer E, Kanlikama M, Bayazit YA, Mumcuç S, Sari I, Gök A. A unique case of an epidermoid cyst of the pterygopalatine fossa and its management. *Int J Pediatr Otorhinolaryngol.* 2003;67:1259-6.
16. Orell SR, Sterrett GF, Whitaker D. Skin and subcutis. In: Orell SR, Sterrett GF, Whitaker D, editors. *Fine Needle Aspiration Cytology.* 4th ed. New Delhi: Elsevier Limited, 2005; 395.
17. Gomi M, Naito K, Obayashi O. A large epidermoid cyst developing in the palm: a case report. *Int J Surg Case Rep.* 2013;4(9):773-777.
18. Debaize S, Gebhart M, Fourrez T, Rahier I, Baillon JM. Squamous cell carcinoma arising in a giant epidermal cyst: a case report. *Acta Chir.* 2002;102(3):196-8.