

Morphometric Study on Wormian Bone of Dry Adult Skull of Nepalese Population

Shrestha A, Khan GA

Department of Anatomy,
School Of Basic Sciences,
Chitwan Medical College,
Kailash Nagar, Bharatpur-5, Chitwan, Nepal.

Corresponding Author

Amit Shrestha
Department of Anatomy,
School Of Basic Sciences,
Chitwan Medical College,
Kailash Nagar, Bharatpur-5, Chitwan, Nepal.
E-mail: kuleshworamit7@gmail.com

Citation

Shrestha A, Khan GA. Morphometric Study on Wormian Bone of Dry Adult Skull of Nepalese Population. *Kathmandu Univ Med J.* 2023;84(4):372-5.

ABSTRACT

Background

Accessory (supernumerary bone) is small irregular worm like bone. These bones are also known as wormian bone. Accessory bone develops when additional ossification centers appear and form extra bones. Many bones develop from several ossification centers of ossification and these separate parts normally fuse. Sometimes one of these centers fails to fuse with main bone. Circumscribed areas of bone are seen along the sutures of the cranium where flat bones about, particularly related to parietal bone.

Objective

To investigate presence and to determine morphologic and morphometric characteristics of wormian (sutural) bones.

Method

The study was conducted on 25 dry human skulls with unknown gender, ethnicity and race in Department of Anatomy, School of Basic Sciences, Kailashnagar, Bharatpur-5, Chitwan Nepal. The study was conducted on 25 dry human skulls with unknown gender, ethnicity and race in Department of Anatomy, School of Basic Sciences, Kailashnagar, Bharatpur-5, Chitwan Nepal. The deformed skull and skull of pediatrics age group are excluded. The location, shape, number and side of Wormian bone are determined. The SPSS 20 program and descriptive statistical method analysis were used for data analysis.

Result

Total 25 adult dry skulls were observed in the study. Both sides of skull were observed. Out of 25 skulls Wormian bones are not found in left sided three lambdoidal suture (four percent).

Conclusion

The knowledge of Wormian bones plays a major role for the neurosurgeons, neuro-anatomists, radiologists, forensic experts and anthropologist. Presence of few bones are normal. But multiple Wormian bones need attention as it may have underlying skeletal or central nervous system pathology. In radiographs they mimic fracture lines. Wormian bone at pterion may produce complications in neurosurgical procedures like burr holes.

KEY WORDS

Skull, Suture, Wormian bone

INTRODUCTION

The human skull consists of 25 bones that fuse together after birth. These bones are divided into viscerocranium and Neurocranium bones. These bones are connected with cranial sutures.¹ Wormian bones are described by Danish Anatomist Olaus Wormian in 1643 A.D. Ossa wormiana was used as term by Thomas Bartholin for those bone firstly.²

Accessory (supernumerary bone) is small irregular worm like bone. These bones are also known as Wormian bone. Accessory bone develops when additional ossification centers appear and form extra bones. Many bones develop from several ossification centers of ossification and these separate parts normally fuse. Sometimes one of these centers fails to fuse with main bone. Circumscribed areas of bone are seen along the sutures of the cranium where flat bones abut, particularly related to parietal bone.³

The aim of the present study was to investigate incidence and to determine morphologic and morphometric characteristics of Wormian (sutural) bones.

METHODS

The study was conducted on 25 dry adult human skulls with unknown gender, ethnicity and race in Department of Anatomy, School of Basic Sciences, Kailashnagar, Bharatpur-5, Chitwan Nepal. The deformed skull and skull of pediatrics age group are excluded. The location, shape, number and side of Wormian bone are determined. The ethical approval is granted as CMC-IRC/078/079-292 by IRC, CMC. The SPSS 20 program and descriptive statistical method analysis were used for data analysis.

RESULTS

Total 25 adult dry skulls were observed in the study. Both sides of skull were observed. Out of 25 skulls Wormian bones are not found in left sided three lambdoidal suture (four percent).

Table 1. Showing Location of Wormian Bone (n=25)

Location	Right Side (n=25)	Left Side (n=25)	Total (n=50)
Lambdoidal suture	25(100)	22(88)	47(96)
Parietomastoid suture	25(100)	25(100)	50(100)
Occipitomastoid suture	25(100)	25(100)	50(100)
Asterion	25(100)	25(100)	50(100)
Pterion	25(100)	25(100)	50(100)
Bregma	25(100)	25(100)	50(100)
Lambda	25(100)	25(100)	50(100)
Coronal suture	25(100)	25(100)	50(100)
Sagittal suture	25(100)	25(100)	50(100)

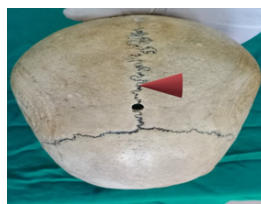


Figure 1. Picture Showing Wormian Bone in Sagittal Suture (Maroon Colored arrow).




Figure 2. Picture Showing Wormian Bone in Sagittal Suture, Coronal Suture and Bregma (red colored arrow sagittal suture, Black circle marked Bregma and yellow colored arrow Coronal Suture).

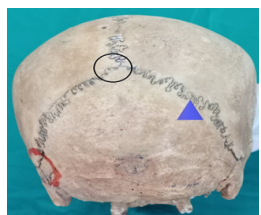


Figure 3. Picture Showing Wormian bone in lambdoidal suture and lambda. (Blue arrowed marked lambdoidal suture, Black circle lambda)

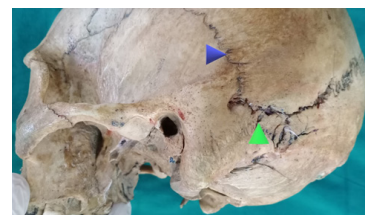


Figure 4. Picture showing Wormian bone in Occipitomastoid and Parietomastoid Suture. (Green arrowed marked occipitomastoid suture, Blue arrow marked parietomastoid suture, Black circle lambda)

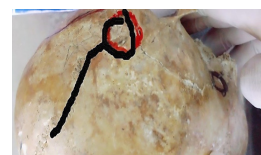

Figure 5. Picture Showing absence of Wormian bone at Left Lambdoidal suture (Blacked marked).



Figure 6. Picture Showing Wormian Bone in Asterion (Orange encircled areas).

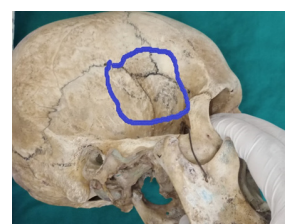


Figure 7. Picture showing Wormian bone in Pterion (Blue encircled area).

DISCUSSION

The present study deals with study of number and location of Wormian bone in dry adult skull of Nepalese population. The finding of present study shown that Wormian bone was absent in three left sided lambdoidal suture. Thus, the present study showed higher incidence of Wormian bone.

Sah et al. reported-on study conducted on eighty dry adult skulls. The result showed out of 55 skulls with Wormian bones, 35 (63.63%) skulls showed Wormian bones at the lambdoidal suture, at the asterion in 11 (20%) skulls, at the pterion in seven (12.72%) skulls, at sagittal suture in

two (3.63%) skulls, none of the skulls showed the Wormian bones at coronal suture and bregma.⁴

Somani et al. reported-on study conducted on 188 skulls showed that Wormian bones were most commonly located in lambdoid suture (40/188, 21.28%), followed in order of frequency by sagittal suture (14/188, 10.77%). Only two cases showed Wormian bone in coronal suture (1.06%, 2/188).⁵

Safak et al. conducted a study on 28 dry adult skull bones. The finding of the study showed that presence of Wormian bone was 42.86% (n=12) and most of them were located on lambdoid suture (57.14%). Wormian bones were seen at lambdoid suture at a rate of 62.5%, occipito-mastoid suture 9.37%, asterion 18.76%, lambda 9.37% and were not seen on pterion, bregma, parietotemporal, sagittal and coronal sutures. Wormian bones were seen on left side at a rate of 65.62% and 34.38% on right side of skull.⁶

Li et al. conducted a study on 285 adult Chinese skulls. The results showed that among the specimens, 182 had Wormian bones, which corresponds to 63.86% (182/285). The locations of the Wormian bones in the order of decreasing prevalence were as follows: the lambdoid suture (78.57%, 143/182), pterion (34.62%, 63/182), asterion (12.09 percent, 22/182), lambda (8.24 percent, 15/182), sagittal suture (4.95%, 9/182), and Inca bone (3.85 percent, 7/182).⁷

Patil et al. studied 180 skull bone revealed that Wormian bones occurred more frequently at lambdoid suture 56 (60%) with incidence of 22 (39.3 %) in male skulls and 34 (60.7%) in female skulls. Wormian bones along the coronal suture and at bregma seen only in male skulls, while intra-orbital seen only in female skulls.⁸

Shone Vasudeo Durge performed study on 160 human skulls. The incidence of Wormian bones was seen in 72 (45 percent) out of one hundred sixty skulls. In the female skull Wormian bone was found to be 42 (47.72 percent) and among the male skull it was found to be 30 (41.66%). Wormian bones occurred more frequently at lambdoid suture 56 (77.77 percent) with incidence of 22 (39.28 percent) in male skulls and 34 (60.71 percent) in female skulls.⁹

Goyal et al. conducted a study on 147 skulls. Wormian bones was seen in 52 skulls (35.3%), with males having 23.8% and females having 11.5 percent and the highest number of Wormian is observed along the lambdoid suture.¹⁰ Uchewa et al. studied 22 adult male skulls over five years period showed that 45.46% of Wormian bones found in this study while 54.55% of the skulls had no Wormian bones present. Eight skulls (36.36%) out of twenty-two skulls have Wormian bones at the lambdoid suture.¹¹

Patel et al. revealed about the study on 27 adult skull overall incidence of Wormian bone was 44.4%. They occurred more frequently at lambdoid suture (48.14%). Wormian

bones were present at asterion (18.5%), along the coronal suture (0.03 percent), along the parieto-temporal suture (0.07%), along the occipito-mastoid suture (0.03%), and at pterion (0.03%). Wormian bones were found 48.1 percent on left half of skull and 37.03% on right half of skull.¹²

Natsis et al. studied 166 Greek adult skulls. 124 (74.7 percent) skulls had Wormian bone. Wormian bones were most commonly located in the lambdoid suture (44.6%), followed in order of frequency by the coronal suture (39.8%), asterion (21% on the left and 15.3% on the right side) and parietomastoid suture (15.1% on the left and 13.9% on the right side).¹³

Himabindu et al. studied 50 adult skulls for the sutural bones in relation to different sutures and fontanelle of the skull. This study showed Wormian bones in lambdoid suture, at pterion, asterion and in the squamous suture. A rare interparietal bone was also found in this study. Four skulls showed Wormian bones in the lambdoid. A single skull showed multiple Wormian bones (27) at lambda and along lambdoid suture. These were eight at lambda, six Wormian bones on the left side and 13 on the right side of the lambdoid suture.¹⁴

Seems et al. also reported multiple Wormian bones at the lambdoid suture in one skull.¹⁵ Observations made by Masih et al. in the study conducted at Rajasthan were in contrary with our results.¹⁶ Additionally, Anitha et al. reported a greater prevalence of wormian bone in the lambdoid suture.¹⁷ Ghosh et al. also observed in their study that 18 (15%) skulls had a single wormian bone and 36 (30%) skulls had multiple wormian bones.¹⁸ In a study done by Saxena et al. in Nigeria incidence of wormian bones was 2.5% which was very less as compared to our study.¹⁹ Lesser wormian bones were found in the study by Shankar et al. than in the current investigation.²⁰ The coronal and sagittal sutures did not include any wormian bones, according to Tewari et al.²¹

With the exception of constitutional bone illnesses, Marty et al. examined the incidence of wormian bones on 605 CT brain scans from children in the normal kid population in France. They discovered an incidence of 53%, which was higher than our study.²² Vinay et al. conducted a study which showed that in 115 (52.99%) of the skulls, wormian bones are primarily observed along the lambdoid suture, either one or two in number. Only two skulls had multiple Wormian bones visible.²³

In the people of South India, wormian bones are quite rare. Just 19% of it according the study of Padmaja et al.²⁴ With 61.2% of sutural bones seen at the lambdoid suture, it was the most common place; 10.6% of all sutural bones found were found at the coronal sutures, which was the second most common site in a study conducted by Ravikant et al.²⁵

According to the Singh R 190 (380 sides) skulls containing the Wormian bones were found; 186 of these were on the

right side and 108 on the left. Lambdoid suture was the predominant sutural bone location, followed by sagittal suture. Lambda was the Wormian bone location that was least frequent.²⁶

The study with limited sample size which represents the limited sample population conducted in limited study period.

CONCLUSION

The Wormian bones are present in sutures. These bones are seen in all suture bones except three left sided lambdoidal suture. The knowledge of Wormian bones may also play

a major role for the neurosurgeons, neuro-anatomists, radiologists, forensic experts and anthropologist Presence of few bones are normal. But multiple Wormian bones need attention as it may have underlying skeletal or CNS pathology. In radiographs they mimic fracture lines. Wormian bone at pterion may produce complications in neurosurgical procedures like burr holes.

ACKNOWLEDGEMENT

We would like to thank the CMC IRC for ethical clearance and whole heartedly thank the administration and department without whom the study would not have been possible.

REFERENCES

1. Reveron RR. Anatomical classification of sutural bones. *MOJ Anat Physiol*. 2017;3(4):130-1.
2. Sreekanth T, Samala N. Morphological study of wormian bones in dried adult human skulls in Telangana. *Int J Anat Res*. 2016:3157-62.
3. Moore KL, Dalley AF. Clinically Oriented Anatomy. 6th ed. Philadelphia: Wolters Kluwer| Lippincott William and Wilkins; c2010. Chapter 1 Introduction to Clinically Oriented Anatomy; p.26.
4. Sah SK, Chaudhary D, Pandey N. Study of Metopism and Wormian Bones in Dry Skulls of Human Cadavers in Nepal. *Int J Anat Res*. 2017; 5(1):3443-3446. DOI: 10.16965/ijar.2016.499.
5. Somani M, Yadav SS, Kumar S, Kumar V. Study of Incidence of Wormian Bones in Eastern Haryana - A Prospective Observational Study. *Sch J App Med Sci*. 2021 Aug 9(8): 1256-1259. DOI: 10.36347/sjams. 2021.v09i08.003.
6. Safak N, TAŞKIN ŞENOL RÜ, YÜCEL A. Morphologic and morphometric evaluation of the wormian bones. *Int J Morphol*. 2020;38(1).
7. Li JH, Chen ZJ, Zhong WX, Yang H, Liu D, Li YK. Anatomical characteristics and significance of the metopism and Wormian bones in dry adult-Chinese skulls. *Folia Morphol (Warsz)*. 2023;82(1):166-175. doi: 10.5603/FM.a2022.0006. Epub 2022 Jan 31. PMID: 35099043.
8. Patil M, Sheelavant S. Sexual dimorphism among the Wormian bones in adult human skulls. *J Indian Acad Forensic Med*. 2012;34(2):124-7.
9. Durge SV. Study of Wormian Bones on Dry human skull and its sexual dimorphism in the region of Andhra Pradesh. *Asterion*. 2016;2:0.
10. Goyal N, Garg A, Kumar Y. Incidence and medicolegal significance of wormian bones in human skulls in North India Region. *Int J App Basic Med Res*. 2019; 9:165-8. DOI: 10.4103/ijabmr.IJABMR_89_19.
11. Uchewa OO, Egwu OA, Egwu AJ, Nwajagu GI. Incidence of wormian bones in the dried skull of Nigerian males. *Int J Anat Var*. 2018 Mar;11(1):32-4.
12. Patel D, Chauhan K, Patil D. Morphological study of wormian bones in dried human skulls. *NJMR*. 2015 Sep 30;5(03):222-5.
13. Natsis K, Piagkou M, Lazaridis N, Anastasopoulos N, Nousios G, Piagkos G, et al. Incidence, number and topography of Wormian bones in Greek adult dry skulls. *Folia morphologica*. 2019;78(2):359-70.
14. Himabindu A, Rao BN. An Insight into Wormian Bones. *IJSRES*. 2(6), June 2015. ISSN: 2349-8862.
15. Seema PV, Mahajan A. Human skull with complete metopic suture and multiple sutural bones at lambdoid suture a case report. *Int J Anat Var*. 2014 Jan 1;7(1).
16. Masih WF, Gupta S, Chand AE, Jaiswal P, Saraswat PK. Incidence of wormian bone in human skulls in Rajasthan. *J Evol Med Dent Sci*. 2013 Mar 4;2(9):1001-5.
17. Anitha V, Jalharish G, Rishi SM, Rishwanth VH. Wormian Bones-An Original Research Article. *Int J Sci Res*. 2017;6(10):782-4.
18. Ghosh SK, Biswas S, Sharma S, Chakraborty S. An anatomical study of wormian bones from the eastern part of India: is genetic influence a primary determinant of their morphogenesis? *Anat Sci Int*. 2017 Jun; 92:373-82.
19. Saxena SK, Chowdhary DS, Jain SP. Interparietal bones in Nigerian skulls. *J Anat*. 1986 Feb; 144:235.
20. Shankar S, Chawla H, Kumar R, Tyagi A, Vashishtha B, Panchal J. Study of incidence of wormian bones in southern Haryana-A prospective observational study. *Indian J Forensic Community Med*. 2020;7(3):129-33.
21. Tewari PS, Malhotra VK, Agarwal SK, Tewari SP. Preinterparietal bone in man. *Anat Anz*. 1982 Jan 1;152(4):337-9.
22. Marti B, Sirinelli D, Maurin L, Carpentier E. Wormian bones in a general pediatric population. *Diagn Interv Imaging*. 2013 Apr 1;94(4):428-32.
23. Kumar V, Gupta M. Incidence of wormian bones along lambdoid suture in Western Uttar Pradesh dried skulls. *Indian J Clin Anat Physiol*. 2017 Apr;4(2):225-6.
24. Padmaja S, Thenmozhi MS, Lakshmanan G. Prevalence of wormian bones in dried adult human skulls of South Indian population-An osteomorphometric study. *Drug Invention Today*. 2019 Apr 15;12(4).
25. Narayan RK, Kumari S, Verma M. Prevalence and variety of sutural bones in densely populated East Indian state of Bihar. *AAMS*. 2019 (No. 73, pp. 174-181). Śląski Uniwersytet Medyczny w Katowicach.
26. Singh R. Wormian Bones: Prevalence, Topography, and Implications. *J Craniofac Surg*. 2024 Jan 1;35(1):247-50.