

Semi-customized Scleral Shell Prosthesis for a Pthisical Eye

Ghimire P,¹ Singh SK,² Rijal AH³

¹Consultant Prosthodontist,
Dental Department, Methinkot Hospital,
Kavrepalanchok, Nepal.

²Consultant Prosthodontist,
Dental Department, Gajendra Narayan Singh,
Sagarmatha Zonal Hospital, Saptari, Nepal.

³Department of Periodontology and Oral Implantology,
Kathmandu University School of Medical Sciences,
Kavrepalanchok, Nepal.

Corresponding Author

Pratistha Ghimire
Consultant Prosthodontist, Dental Department,
Methinkot Hospital, Kavrepalanchok, Nepal.
E-mail: pratistha812@gmail.com

Citation

Ghimire P, Singh SK, Rijal AH. Semi-customized Scleral Shell Prosthesis for a Pthisical Eye. *Kathmandu Univ Med J.* 2023;84(4):460-3.

ABSTRACT

One of the most common causes of eye loss is ocular trauma that overtime results in shrunken, non-functional eye known as a pthisical eye. The prosthetic options for such case include either prefabricated prosthesis or custom-made prosthesis. Various materials and techniques are used for the fabrication of the prosthesis. Semi-customized prosthesis uses stock iris while the scleral shell is customized. This prosthesis has the advantages of both stock and custom-made prosthesis providing functionally and esthetically satisfactory result. This case report demonstrates the case of a 32 years old male who reported to the Department of Prosthodontics and Crown-Bridge, College of Dental Surgery, BP Koirala Institute of Health Sciences, Dharan, Nepal for eye prosthesis to mask his pthisical eye. For this case, a semi-customized scleral shell prosthesis was planned and fabricated.

KEY WORDS

Ocular prosthesis, Pthisical eye, Scleral shell

INTRODUCTION

Though the exact origin of “The eye is the window to the soul” is unclear, it reveals the significance of eye only in one aspect of a person’s life. Eyes are considered as the most important symbolic sensory organ but, not everyone is blessed to have these organs throughout their lives. The most common etiologies of eye loss include malignancy, infection and trauma.^{1,2} Ocular trauma causes reduced aqueous production resulting in shrunken, non-functional eye termed as “Pthisical eye”.³ The disfigurement associated with the loss or abnormality of an eye causes significant physical and emotional problems to the patient.^{1,4} Ocular prosthesis is essential to promote physical and psychological healing along with social acceptance. Prosthesis characterization can be done by incorporating materials that simulate blood vessels.⁵ Ocular prostheses can either be ready-made stock shell, tailoring the stock eye or custom-made.^{6,7} Fabrication of a custom ocular prosthesis shows improved adaptation to tissue bed, distributes uniform pressure and provides a more esthetic and precise result.⁸

CASE REPORT

A 32 years old male reported to the Department of Prosthodontics and Crown- Bridge, College of Dental Surgery, BPKIHS, Dharan, Nepal with a defect in his right eye and had the desire to have an artificial right eye. The patient’s history revealed an episode of ocular trauma 10 years back due to penetrating injury to the right eye for which evisceration was done but no ocular prosthesis was placed then. Over time, it led to the shrinkage of eye, leaving an ocular defect that resulted in pthisical right eye (Fig. 1).

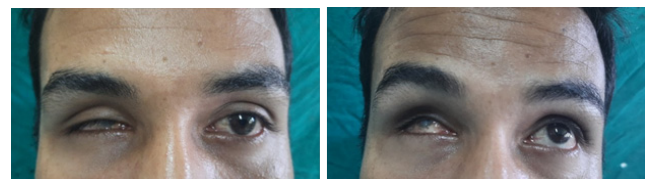

Figure 1. Pretreatment photographs of the patient.

Physical evaluation of the defect revealed adequate healing of the socket with absence of infection. The size

and extent of the socket as well as the depth of fornices were also noted. Muscular evaluation revealed good muscular control of the palpebrae and mobility of the posterior wall of the defect. Psychological appraisal of the patient was done regarding the desires and expectations of the prosthesis. The patient was counseled regarding the expected results, with specific emphasis on his role both during the treatment phase and after the completion of the prosthesis.

Based on the history and examination findings, treatment plan was made to fabricate a semi-customized scleral shell prosthesis with respect to the right eye. The treatment procedures were explained to the patient and with the patient's informed consent, the treatment was begun.

The patient's eyelashes and defect site were coated with Vaseline jelly prior to impression making. Preliminary impression was made using a thin mix of alginate impression material (Zelgan 2002, Dentsply) loaded into a 5 ml syringe (Fig. 2).

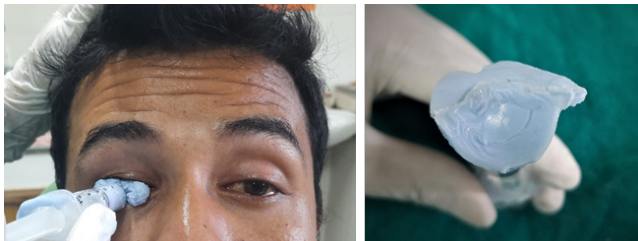

Figure 2. Preliminary impression with irreversible hydrocolloid.

Diagnostic cast was made by pouring the impression with dental stone in two sections to obtain two-piece mold. Custom tray was fabricated using clear acrylic resin, the center of which was connected to the needle cap of 5 ml syringe for the passage of secondary impression material (Fig. 3).




Figure 3. Fabrication of custom tray with clear acrylic with attached needle cap.

With patient seated in upright position and head rest on dental chair, final impression was made with light-body impression material (Reprosil, Dentsply) loaded onto the custom tray (Fig. 4). The patient was asked to close his eyes to allow excess material to flow out, perform various eye movements for recording the functional impression and then asked to hold his gaze in forward position.

The final impression was poured in two sections. The first section was poured in die stone (Kalrock, Kalabhai Dental, India). Keyways were made, separating medium

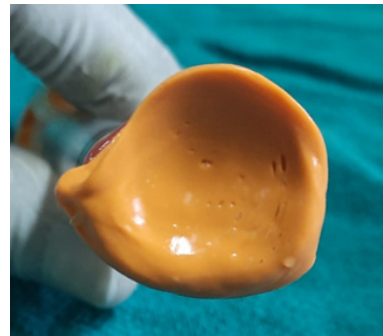


Figure 4. Final impression.

was applied and second pour was done with dental stone (Kalstone, Kalabhai Dental, India). On separation of these sections, a funnel shaped hole around the needle cap was created which was then used to fill the mold with molten baseplate wax to fabricate wax pattern or wax conformer (Fig. 5).

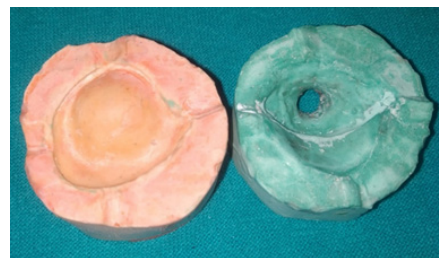

Figure 5. Pouring of final impression.

Molten baseplate wax was poured via the channel created (Fig. 6).

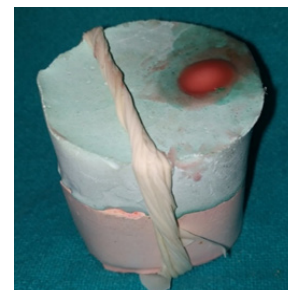

Figure 6. Pouring the molten wax.

After the wax has solidified, casts were separated and the wax pattern was retrieved and try-in was done (Fig. 7).

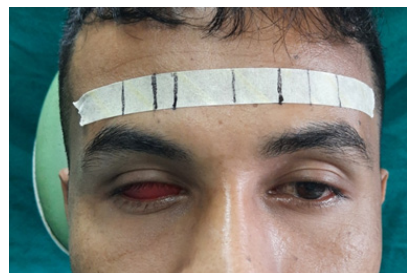

Figure 7. Try-in of wax conformer.

With the patient's head held upright, he was instructed to move both the conformer and the natural eye in various directions. The wax pattern was checked for proper fit and contours and was adjusted accordingly (Fig. 8).

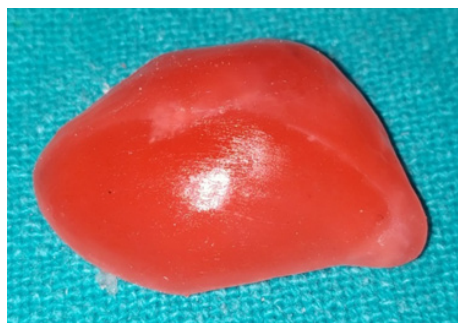

Figure 4. Prepared wax pattern.

After the scleral wax pattern has been approved, a stock eye shell was selected to match the size and shade of contralateral iris. Iris button was removed from the stock eye using acrylic trimming bur. This stock iris was positioned on the scleral wax pattern, and the border was sealed using a hot wax spoon. The position of iris was determined by centering in relation to the inner and outer canthus of eyes as well as upper and lower lids. This was verified by taking various reference lines marked in leukoplast stuck to patient's forehead (Fig. 9). Shade selection for the sclera was done using natural eye as a guide.

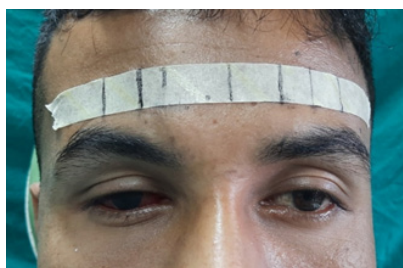

Figure 9. Stock iris positioning and verification.

Scleral wax pattern with the stock iris positioned over it was removed from the socket and washed under tap water. To stabilize the stock iris within the mold during flasking, an acrylic mount was fabricated using auto polymerizing acrylic resin (DPI-Self cure, Dental products of India Ltd.) extension of a diameter of around 4 mm and length of around 6 mm was attached over its center. Flasking and dewaxing were done in a conventional manner (Fig. 10).

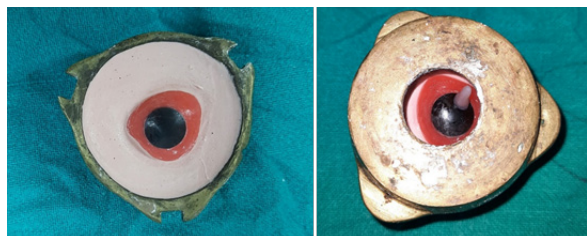


Figure 10. Wax pattern fitted with acrylic mount.

After dewaxing, the mold obtained was cleaned and prepared for packing (Fig. 11).

After dewaxing procedure, packing and curing were done using the selected shade of heat cure tooth colored acrylic resin (DPI Heat polymerised tooth colored acrylic resin, Mumbai, India). Red nylon fibers were retrieved from the polymer and placed for mimicking the blood vessels (Fig.

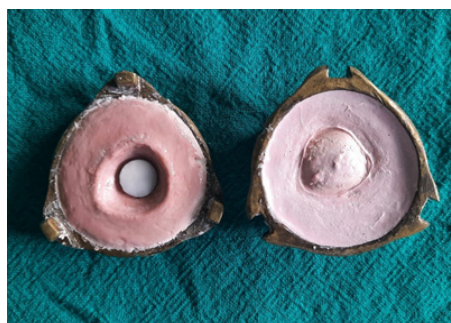

Figure 11. After dewaxing.

12). Clear acrylic mono poly syrup was prepared using clear acrylic (Coltene Heat cure denture base polymer resin) (Fig. 12) and coated onto the die surface of the scleral pattern to secure the fibers in place and was allowed to dry. The mold was then packed with selected shade of resin and acrylization was done by following a long curing cycle.

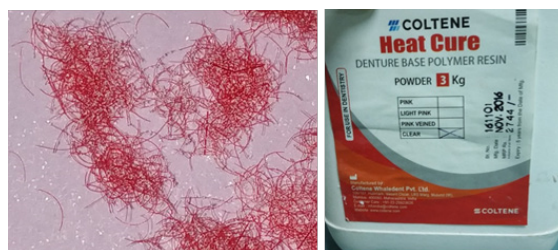


Figure 12. Red fibres extracted from the polymer and clear heat cure acrylic resin.

The scleral shell prosthesis was retrieved from the mold. Gross and fine finishing as well as pol-ishing was done and the final prosthesis was obtained (Fig. 13).

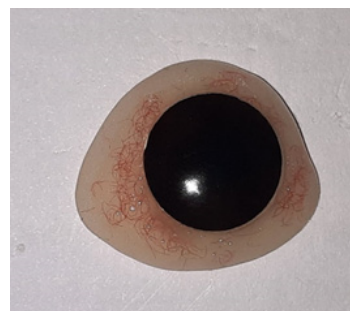

Figure 13. Final scleral shell prosthesis.

After disinfection of the finished prosthesis, it was inserted into the patient's right eye. All the necessary adjustments were done and the final scleral shell prosthesis was evaluated for retention, comfort, fit and ease of functional eye movements (Fig. 14).



Figure 14. Post-prosthetic rehabilitation of patient.

The patient was taught how to place and remove the prosthesis on his own. Instructions were given regarding the care and maintenance of the prosthesis. The patient was informed that re-polishing of the prosthesis may be required on a timely basis and was kept on a periodic follow-up visit (Fig. 15).



Figure 15. Six months follow-up of the patient.

DISCUSSION

Eyes are the most characteristic and noticeable feature of face. Loss of an eye is not only physical but also emotional, social and psychological loss to the patient.¹ Prosthetic rehabilitation of lost eye can be done with use of prefabricated and custom-made eye prosthesis. The prosthesis, though not functional, is an esthetic replacement and restores self-confidence in patients and prevents social embarrassment. The Scleral Shell Prosthesis is a thin hard acrylic shell-like artificial eye. This type of eye prosthesis is worn over a damaged, disfigured eye or eviscerated globe.⁹

In this case report, semi-customized scleral shell prosthesis was fabricated. Its advantages over prefabricated prosthesis include better fit, close adaptation, patient comfort and good natural esthetic outcome. It also overcomes the complex painting procedure and technique involved in making a custom-made ocular prosthesis, which are often time consuming and based purely on the painting skills of the operator.¹⁰⁻¹³

The main disadvantage to the use of stock iris is its inability to match iris colors. But, Taicher in 1985 mentioned that the main limitation of modified prefabricated eye is not iris color but the limited variations in iris size.¹³ Fortunately, only a few patients cannot be accommodated by this technique.¹³

Although, a custom-made prosthesis may still be necessary for some, most patients can be treated with modified prefabricated-prosthesis with excellent results. It gives better esthetic and functional outcome than stock ocular prosthesis, restores the self-esteem of the patient and allows them to confidently face the world rather than hiding behind the dark glasses.

ACKNOWLEDGMENTS

I would like to acknowledge all the faculties of Department of Prosthodontics and Crown-Bridge, College of Dental Surgery, BPKIHS, Dharan, Nepal for helping us to complete the case.

REFERENCES

- Lubkin V, Sloan S. Enucleation and psychic trauma. *Adv Ophthalmic Plast Reconstr Surg.* 1990;8:259-62. PMID: 2248718.
- Raflo GT. Enucleation and evisceration. *Duane's clinical ophthalmology.* 1995;5(2):1-25.
- Schmack I, Völcker HE, Grossniklaus HE. Ch. 54 - Phthisis bulbi. In: Levin LA, Albert DM, editors. *Ocular Disease.* Edinburgh: W.B. Saunders; 2010.
- Beumer J, Curtis T, Marunick M. Maxillo Facial Rehabilitation: Prosthodontic and surgical consideration. In: *Maxillo Facial Rehabilitation: Prosthodontic and surgical consideration: second ed.* Ishiyaku Euro America, Inc.; 1996.
- Erpf SF. Comparative features of plastic and/or glass in artificial-eye construction. *Arch Ophthalmol.* 1953;50:737.
- Patil SB, Meshramkar R, Naveen BH, Patil NP. Ocular prosthesis: a brief review and fabrication of an ocular prosthesis for a geriatric patient. *Gerodontology.* 2008 Mar;25(1):57-62. doi: 10.1111/j.1741-2358.2007.00171.x. PMID: 18289132.
- Guttal SS, Patil NP, Vernekar N, Porwal A. A simple method of positioning the iris disk on a custom-made ocular prosthesis. A clinical report. *J Prosthodont.* 2008 Apr;17(3):223-7. doi: 10.1111/j.1532-849X.2007.00272.x. Epub 2007 Nov 28. PMID: 18047488.
- Ow RK, Amrith S. Ocular prosthetics: use of a tissue conditioner material to modify a stock ocular prosthesis. *J Prosthet Dent.* 1997 Aug;78(2):218-22. doi: 10.1016/s0022-3913(97)70129-x. PMID: 9260142.
- Somkuwar K, Mathai R, Jose P. Ocular prosthesis: Patient rehabilitation. *Peo J Sci Res.* 2009;21(2):21-6.
- Kumar P, Aggrawal H, Singh RD, Chand P, Jurel SK, Alvi HA, et al. A simplified approach for placing the iris disc on a custom made ocular prosthesis: report of four cases. *J Indian Prosthodont Soc.* 2014 Mar;14(1):124-7. doi: 10.1007/s13191-012-0179-9. Epub 2012 Oct 18. PMID: 24605010; PMCID: PMC3935045.
- Reis RC, Brito e Dias R, Mesquita Carvalho JC. Evaluation of iris color stability in ocular prosthesis. *Braz Dent J.* 2008;19(4):370-4. doi: 10.1590/s0103-64402008000400015. PMID: 19180330.
- Cain JR. Custom ocular prosthetics. *J Prosthet Dent.* 1982 Dec;48(6):690-4. doi: 10.1016/s0022-3913(82)80030-9. PMID: 6961208.
- Taicher S, Steinberg HM, Tubiana I, Sela M. Modified stock-eye ocular prosthesis. *J Prosthet Dent.* 1985 Jul;54(1):95-8. doi: 10.1016/s0022-3913(85)80079-2. PMID: 3860663.